

1-31-2016

# Current Status Of Direct Pulp-Capping Materials For Permanent Teeth

Takashi Komabayashi

*The University of New England, tkomabayashi@une.edu*

Qiang Zhu

*University of Connecticut - Stamford*

Robert Eberhart

*University of Texas Southwestern Medical Center*

Yohji Imai

*Tokyo Medical and Dental University*

Follow this and additional works at: [http://dune.une.edu/cdm\\_facpubs](http://dune.une.edu/cdm_facpubs)



Part of the [Dentistry Commons](#)

---

## Recommended Citation

Komabayashi, Takashi; Zhu, Qiang; Eberhart, Robert; and Imai, Yohji, "Current Status Of Direct Pulp-Capping Materials For Permanent Teeth" (2016). *Dental Medicine Faculty Publications*. Paper 2.

[http://dune.une.edu/cdm\\_facpubs/2](http://dune.une.edu/cdm_facpubs/2)

This Article is brought to you for free and open access by the College of Dental Medicine at DUNE: DigitalUNE. It has been accepted for inclusion in Dental Medicine Faculty Publications by an authorized administrator of DUNE: DigitalUNE. For more information, please contact [bkenyon@une.edu](mailto:bkenyon@une.edu).

## Current status of direct pulp-capping materials for permanent teeth

Takashi KOMABAYASHI<sup>1</sup>, Qiang ZHU<sup>2</sup>, Robert EBERHART<sup>3</sup> and Yohji IMAI<sup>4</sup>

<sup>1</sup> University of New England College of Dental Medicine, 716 Stevens Avenue, Portland, ME 04103, USA

<sup>2</sup> University of Connecticut School of Dental Medicine, 263 Farmington Avenue, Farmington, CT 06030, USA

<sup>3</sup> University of Texas Southwestern Medical Center, 1801 Inwood Road, Dallas, TX 75235, USA

<sup>4</sup> Tokyo Medical and Dental University, 1-5-45 Yushima, Bunkyo-ku, Tokyo 113-0034, Japan

Corresponding author, Takashi KOMABAYASHI; E-mail: [tkomabayashi@une.edu](mailto:tkomabayashi@une.edu), [icd38719@nifty.com](mailto:icd38719@nifty.com)

Direct pulp-capping is a method for treating exposed vital pulp with dental material to facilitate the formation of reparative dentin and to maintain vital pulp. Two types of pulp-capping materials, calcium hydroxide and mineral trioxide aggregate, have been most commonly used in clinics, and an adhesive resin has been considered a promising capping material. However, until now, there has been no comprehensive review of these materials. Therefore, in this paper, the composition, working mechanisms and clinical outcome of these types of pulp-capping materials are reviewed.

**Keywords:** Pulp-capping, Calcium hydroxide, Mineral trioxide aggregate (MTA), Methyl methacrylate-tributylborane (MMA-TBB) resin, Artificial dentin bridge

### INTRODUCTION

There are three causes of vital pulp exposure: caries, mechanical sources and trauma. If pulp exposure occurs before caries is completely removed, it is considered caries exposure. If pulp exposure occurs during the preparation of a cavity without caries, it is called mechanical exposure. Mechanical exposures are typically due to a misadventure during tooth preparation. Traumatic pulp exposure may result from a sports injury when the coronal part of the tooth is chipped. In the event of exposure in vital pulp, direct pulp-capping, pulpotomy or pulpectomy could be the treatment choices.

Direct pulp-capping is a treatment for exposed vital pulp involving the placement of a dental material over the exposed area to facilitate both the formation of protective barrier<sup>1-3)</sup> and the maintenance of vital pulp<sup>4,5)</sup>. From a more precise clinical perspective, direct pulp-capping is a clinical technique that lies between indirect pulp-capping and pulpotomy. Indirect pulp-capping is a procedure in which a material is placed on a thin partition of remaining dentin where no vital pulp exposure occurs. Pulpotomy differs from pulp-capping only in that a portion of the remaining pulp is removed before the capping material is applied. Accordingly, direct pulp-capping has been used as an alternative approach to the maintenance of vital pulp, thereby avoiding as many as 22 million annual definitive root canal treatments in the United States<sup>6)</sup>. Of these cases, several million fail due to the recurrence of symptoms or through the detection of periradicular disease<sup>7,8)</sup>. Stanley<sup>9)</sup> and Bender<sup>10)</sup> hypothesized that many tooth extractions and root canal treatments could have been avoided through the conservative approach of direct pulp-capping.

Clinical pulp conditions related to patient symptoms are to be considered before the direct pulp-capping

material placement. For evaluating clinical pulp conditions, the most important test is pulp vitality. If the pulp vitality test is negative, pulp necrosis is diagnosed. If the pulp vitality test is positive, then we call the pulp vital pulp. A vital pulp can be divided into three different categories depending on the clinical symptoms: normal pulp, reversible pulpitis, and irreversible pulpitis. Normal pulp has no clinical symptoms. Reversible pulpitis usually has a short-lived thermal sensitivity, which will disappear immediately once the thermal stimulation is removed. Irreversible pulpitis usually has spontaneous and/or lingering pain and it could also have referred pain. Pulp-capping could be performed on tooth with normal pulp or reversible pulpitis. Percussion, palpation, and periodontal probing test results should be within normal limits. The radiograph should show normal apical tissue. The pulp exposure site should be less than 1 mm in diameter and stopping pulpal hemorrhage should be prerequisite before direct pulp-capping material placement. If these requirements cannot be satisfied, the pulp-capping procedure is not recommended.

This review summarizes the current status of direct pulp-capping materials.

### BRIEF HISTORY OF DIRECT PULP-CAPPING MATERIALS

The first documented pulp-capping treatment was conducted in 1756 by Pfaff, using gold foil<sup>1)</sup>. Since then, many agents have been recommended for direct pulp-capping<sup>11,12)</sup>. However, due to insufficient or inappropriate pre-treatment diagnoses, necrotic pulp was historically capped even though it was contraindicated<sup>11)</sup>.

In 1930, Hermann<sup>13,14)</sup> discovered that calcium hydroxide is effective in repairing an exposure site. Since then, calcium hydroxide in the form of powder,

paste and cement has been used with clinical success for facilitating the formation of reparative dentin along with the maintenance of vital pulp, the induction of mineralization and the inhibition of bacterial growth<sup>15,16</sup>. Calcium-hydroxide-based cement was patented in 1962<sup>17</sup>, and the first clinical study of Dycal (Dentsply Caulk, Milford, DE, USA) was reported in 1963, with a success rate of 85% compared with that of 80% for the control calcium hydroxide mixed with saline<sup>18</sup>.

Glass and his colleagues<sup>4</sup> introduced zinc oxide eugenol for direct pulp-capping. However, chronic inflammation and a lack of pulp healing were observed, with no dentin bridge formation. It was later reported that eugenol is highly toxic, and zinc oxide eugenol resulted in high interfacial leakage<sup>19,22</sup>.

In the 1970s, glucocorticoids combined with antibiotics were frequently used in an attempt to control pulpal pain and suppress pulpal inflammation<sup>19,20,23</sup>. Reports of poor wound-healing and even pulpal necrosis emerged, so steroids are no longer used for direct pulp-capping.

For direct pulp-capping, the use of biological molecules, such as growth factors and extracellular matrices, is considered<sup>24</sup>. For example, animal studies showed that growth factors such as bone morphogenetic proteins (BMP) and transforming growth factors (TGF) induced reparative dentin formation<sup>21,24-27</sup>. However, these growth factors are not adequately therapeutic, since they produce a porous osteodentin with tunnel defects<sup>24</sup>. Extracellular matrix (ECM) dentin molecules, such as bone sialoprotein (BSP)<sup>28</sup>, matrix extracellular phosphoglycoprotein (MEPE)<sup>29</sup>, amelogenin<sup>24</sup> and dentin phosphophoryn<sup>30</sup>, have been shown to induce reparative dentin. Capping with ECM molecules is extremely promising, producing a reparative mineralized tissue with structural properties better than those produced in the presence of calcium hydroxide<sup>24</sup>. Among these, amelogenin is suggested to be most promising as a direct capping material. Implantation of two spliced forms of amelogenin with agarose beads as carriers induced the formation of a homogeneous dentinal bridge or massive pulp mineralization<sup>24</sup>.

Direct pulp-capping with resin-modified glass ionomer has been successfully reported in animal studies in monkeys<sup>31,32</sup> and in dogs<sup>33</sup>. However, it was also examined in humans<sup>34</sup>, and no dentin bridge formation was observed in 10 months.

In the 1990s, Torabinejad and White<sup>35</sup> introduced, mineral trioxide aggregate (MTA), which is basically a hydraulic Portland cement or calcium silicate and releases calcium hydroxide slowly while setting. MTA has been used clinically with success rates similar to those achieved with calcium hydroxide<sup>36</sup>. In 2006 and thereafter, MTA-like materials were launched, composed of artificial synthetic calcium silicates instead of Portland cement.

## CURRENT DIRECT PULP-CAPPING MATERIALS

### *Calcium hydroxide*

Calcium hydroxide has been the gold standard for pulp-capping. The effect of calcium hydroxide is regarded as the result of the chemical injury caused by the hydroxyl ions. The initial effect of calcium hydroxide applied to exposed pulp is the development of a superficial necrosis. Firm necrosis causes slight irritation and stimulates the pulp to defend and repair to form a reparative dentin bridge through cellular differentiation, extracellular matrix secretion and subsequent mineralization<sup>37</sup>. While the formation of a dentin bridge has been believed to be the key for the clinical success of direct pulp-capping, it has been reported that 89% of dentin bridges formed by calcium hydroxide cement in monkeys contained tunnel defects<sup>38</sup>. These tunnel defects that form in the heterogeneous dentin bridge not only fail to provide a permanent barrier, but also fail to provide a long-term biological seal against bacterial infection. Another disadvantage of calcium hydroxide is dissolution<sup>39</sup>. This may lead to the formation of a dead space<sup>40</sup> and microleakage<sup>39</sup>.

#### 1. Aqueous calcium hydroxide

Historically, calcium hydroxide powder was applied directly onto the exposed pulp surface. The powder comes into contact with pulpal fluid and forms a paste<sup>41,42</sup>. This technique is not widely used at the present time. In a study in dogs, Eleazer *et al.*<sup>43</sup> reported that calcium hydroxide powder in contact with the pulp caused an inflammatory response. Pereira *et al.*<sup>44</sup>, also in a dog pulp study, reported no differences in pulpal responses to direct pulp-capping achieved with either paste or powder forms in a 120-day period. Aqueous calcium hydroxide paste is used for direct pulp-capping<sup>45-47</sup>. This paste is generally prepared by the mixing of calcium hydroxide powder and water or saline at the time of application in the clinic. Premixed types of the paste indicated for direct pulp-capping are commercially available, such as UltraCal XS (Ultradent Products, South Jordan, UT, USA) and Calcicur (Voco, Cuxhaven, Germany), which also contain barium sulfate for radiopacity and other ingredients to enhance the properties of the material.

The success rates of direct pulp-capping with calcium hydroxide decrease as follow-up periods increase. Rates are more than 90% after 1 to 2 years and drop from 82% to 37% after 2 to 5 years<sup>48</sup>, or to 80%, 68% and 59% after 1, 5 and 9 years, respectively<sup>49</sup>.

Although aqueous calcium hydroxide has been well-accepted clinically, it has drawbacks, including a lack of setting properties and gradual resorption after placement. Another disadvantage is porosities in the newly formed dentin, known as tunnel defects, which can result in microleakage and lead to the loss of tooth vitality and calcification<sup>36</sup>.

#### 2. Calcium-hydroxide-based cement

Because of the disadvantages of aqueous calcium hydroxide described above, a cement type of calcium

hydroxide with setting characteristics was developed and has been widely used in clinical practice since the 1960s.

The most popular commercial cement is Dycal, which consists of catalyst and base mixed at a 1:1 ratio. The catalyst contains calcium hydroxide, N-ethyl-o/p-toluene sulfonamide, zinc oxide, titanium dioxide and zinc stearate, and the base contains 1,3-butylene glycol disalicylate, zinc oxide, calcium phosphate and calcium tungstate. Another product is Life (Kerr, Orange, CA, USA), whose setting reaction mechanism between salicylic acid ester and zinc oxide is similar to that of Dycal, but whose ingredients are different. The base contains calcium hydroxide, zinc oxide and butyl benzene sulfonamide, and the catalyst barium sulfate, titanium dioxide and methyl salicylate.

There are two clinical studies that applied calcium hydroxide cement for direct pulp-capping. Al-Hiyasat *et al.*<sup>50)</sup>, using only radiography, evaluated the 3-year treatment outcome of pulp-capping in teeth in terms of both mechanical and caries exposure. The success rate for mechanical exposure was 92% compared with 33% for the caries-exposure cases. In another study, Barthel *et al.*<sup>51)</sup>, using both radiography and pulp vitality testing, examined the 5- and 10-year treatment outcome of caries exposure in pulp-capped teeth. In this case, the success rates for 5 and 10 years were 37% and 13%, respectively. The majority of the failures were asymptomatic; the pulp tended to become necrotic or slowly calcify. Therefore, direct pulp-capping is considered controversial by many clinicians, and pulpectomy is still the standard procedure for treating caries-exposed inflamed vital pulp with a closed apex. The success rate of pulpectomy is reported to be about 95%<sup>52,53)</sup>.

### Calcium-silicate-based materials

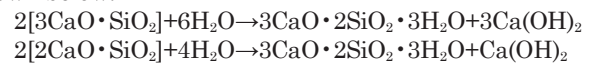
#### 1. Hydraulic cements

##### 1) Mineral trioxide aggregate (MTA)

The original MTA, ProRoot MTA Gray (Dentsply Tulsa Dental Specialties, Johnson City, TN, USA), was marketed in 1998 and was composed of 75% Type I Portland cement, 20% bismuth oxide and 5% calcium sulfate dihydrate. The Portland cement is composed of approximately 55 wt% tricalcium silicate ( $3\text{CaO}\cdot\text{SiO}_2$ ), 19 wt% dicalcium silicate ( $2\text{CaO}\cdot\text{SiO}_2$ ), 10 wt% tricalcium aluminate ( $3\text{CaO}\cdot\text{Al}_2\text{O}_3$ ), 7 wt% tetracalcium aluminoferrite ( $4\text{CaO}\cdot\text{Al}_2\text{O}_3\cdot\text{Fe}_2\text{O}_3$ ), 2.8 wt% magnesium oxide, 2.9 wt% sulfate and 1.0 wt% free calcium oxide. Bismuth oxide and calcium sulfate are the radiopacifier and setting modifier, respectively. ProRoot MTA White was introduced in 2002 and differs from its predecessor in composition, *i.e.*, the elimination of tetracalcium aluminoferrite and an increase of calcium silicates. The gray type of MTA, containing tetracalcium aluminoferrite, and with composition similar to that of the original type, is less popular for esthetic reasons, but several products are available, including: ProRoot MTA Gray, MTA Angelus (Angelus, Londrina, Brazil), Grey MTA Plus (Avalon Biomed, Bradenton, FL, USA), EndoCem MTA (Maruchi, Gangwon-do, Korea) and

Ortho MTA (BioMTA, Daejeon, Korea). MTA without tetracalcium aluminoferrite is more popular, and many products are marketed worldwide: ProRoot MTA White, MTA Angelus White, White MTA Plus (Prevest Denpro, Jammu, India), MM-MTA (Micro Mega SA, Besançon, France), MTA Caps (Acteon, Merignac, France), Tech BioSeal MTA (Isasan S.R.L., Rovello Porro, Italy), Aureose 1 M.T.A. (Ogna Laboratori Farmaceutici, Muggiò, Italy), MTA+product (Cerkamed PPH, Wojciech Pawlowski, Nisko, Poland), Trioxident (VladMiVa, Belgorod, Russia), NEX MTA (GC, Tokyo, Japan) and Endo-Eze MTA (Ultradent Products), among others.

The mechanism of action of MTA is similar to that of calcium hydroxide. The calcium hydroxide produced as a by-product of hydration of MTA is leached out and causes necrosis when in contact with the pulp. When MTA powder is mixed with water at the time of application, calcium silicates in the powder hydrate to produce a calcium silicate hydrate gel and calcium hydroxide, as shown below:



Thus, MTA can be described as a calcium-hydroxide-releasing material and, therefore, is expected to present various properties similar to those described above for calcium hydroxide.

The advantages of MTA are believed to be its sealing ability, biocompatibility, bioactivity and capacity to promote mineralized tissue formation<sup>54-57)</sup>. Also, MTA is suggested to be superior to calcium hydroxide due to its more uniform and thicker dentin bridge formation, less inflammatory response and less necrosis of pulpal tissue<sup>55,56,58-63)</sup>.

An antibacterial effect of MTA is controversial as reviewed by Parirokh and Torabinejad<sup>64)</sup>. MTA showed an antibacterial effect on some of the facultative bacteria but no effect on any of the strictly anaerobic bacteria<sup>65)</sup>. MTA demonstrated, in some cases, albeit inferior to calcium hydroxide or zinc oxide/eugenol paste<sup>66-70)</sup>. Taken together, the antimicrobial activity of MTA may not be as strong as those of traditional calcium hydroxide-based cements and sealers<sup>70)</sup>.

In spite of its many positive properties, some disadvantages of MTA include long setting times, poor handling<sup>71-73)</sup>, and coronal tooth discoloration<sup>74-77)</sup>. Reported setting times have shown variations: 50 min<sup>73)</sup>, less than 4 h<sup>78)</sup> and 70 and 175 min for the initial and final setting times<sup>79)</sup>, respectively. Setting time of MTA Gray (165 min) is shorter than that of MTA White<sup>64)</sup>. A long setting time may be inconvenient to both dentist and patient, because it requires direct pulp-capping with MTA in two visits: application of MTA in the first visit and seating of the permanent restoration over the sufficiently hardened MTA in the second visit. Moreover, it may increase the risk of bacterial contamination. Short setting times will make it possible for treatment to be performed in one visit.

As for the handling characteristics, the “sandy”-feeling mixture produced by the coarse particles of ProRoot and water is difficult to be delivered to the



required site and hard to condense adequately. Setting time and handling properties can be affected by the particle size and distribution as well as by the shape of the MTA powder. The particle sizes of MTA are reported to be from 1 to 10  $\mu\text{m}$ <sup>80</sup>. Angelus White and Gray have median particle size below 10  $\mu\text{m}$ , but contain many particles more coarse than 40  $\mu\text{m}$ , up to 100  $\mu\text{m}$ . Comparisons of particle size and shape were reported among ProRoot MTA, MTA Angelus and ordinary Portland cement. The Angelus particles had relatively low circularity and wide size distribution and were less homogeneous than ProRoot MTA, and ProRoot MTA Gray had many similarities to Portland cement in particle size and distribution. Some particles of MTA were as small as 1.5  $\mu\text{m}$ <sup>81</sup>. Size distribution in ProRoot Gray is greater than in the White<sup>82,83</sup>.

Tooth discoloration has been reported with the use of gray MTA in direct pulp capping<sup>74</sup> and therefore the use of white MTA has generally been recommended in the esthetic zone. However, tooth discoloration associated with white MTA was also described in case reports in endodontic treatments<sup>75,76</sup>. Tooth color change was reported to be induced by both gray and white MTA *in vitro*<sup>77</sup>. Several factors were reported to contribute to tooth discoloration by white MTA: contamination with blood<sup>84,85</sup>, contact with sodium hypochlorite<sup>86</sup>, the presence of light and oxygen<sup>87,88</sup>. The possible involvement of the radiopacifier bismuth oxide in the discoloration is postulated<sup>87</sup>. The reason and mechanism of tooth discoloration are not fully understood and remain to be investigated.

MTA cannot bond to dentin. Therefore, there is a risk of bacterial leakage, which could lead to failure of endodontically treated teeth. The sealing ability of MTA as a root-end filling material was evaluated and compared with that of other materials *in vitro* by several methods. In dye penetration tests, the ascending order of leakage was reported as: MTA<glass-ionomer cement<Super EBA (Bosworth Company, Skokie, IL, USA) [reinforced zinc oxide/eugenol (32%)/*o*-ethoxybenzoic acid (68%) cement]<amalgam<IRM (Intermediate Restorative Material, Dentsply Caulk, Milford, DE, USA) (reinforced zinc oxide-eugenol cement)<sup>89-91</sup>. A bacterial microleakage model study showed: composite resin (Prisma TPH, Dentsply Caulk)<amalgam+bonding agent (Probond Primer & Adhesive, Dentsply Caulk)<EBA, amalgam and MTA<sup>92</sup>. Another bacterial leakage study indicated that MTA and EBA leaked, and that leakage increased with time<sup>93</sup>. The results of a fluid transport model study were: AH26 (Dentsply Maillefer, Ballaigues, Switzerland) (negative control)<<MTA<glass-ionomer cement<EBA<amalgam<sup>94</sup>. The results of marginal adaptation measurement indicated that MTA was better than IRM and Super EBA<sup>95</sup>. A dye leakage study in the orifice of a root canal system indicated: composite resin (Tetric, Ivoclar Vivadent, Schaan, Liechtenstein)<MTA<Cavit (3M ESPE, St. Paul, MN, USA) [zinc oxide/ethylene bis(oxyethylene)diacetate cement]<sup>96</sup>.

When all these results are summarized, it may

be concluded that MTA is better than glass-ionomer cement, EBA cement, amalgam and IRM, but inferior to composite resin and AH26, which is a root canal sealer consisting of epoxy resin, methenamine (hexamethylenetetramine) and bismuth oxide. Thus, it is suggested that the seal provided by MTA should probably be more leakage-proof<sup>97</sup>.

Animal direct pulp-capping studies comparing MTA with calcium hydroxide generally indicate better pulp-healing with MTA than with calcium hydroxide<sup>59,60,62,98-102</sup>. These studies consistently demonstrated more hard-tissue bridge formation and less inflammation in the MTA group compared with the calcium hydroxide group. Also in human studies, many reports agreed that MTA is better than Dycal, with better hard-tissue formation and less pulp tissue inflammation<sup>61,97,103,104</sup>. The biological mechanism by which MTA induces dentin bridge formation is currently unknown. The predictable formation of a quality hard-tissue barrier subjacent to MTA is likely to be multifactorial, involving its sealing ability, biocompatibility and the production of an alkaline pulpal environment<sup>97</sup>.

As for clinical outcome of direct pulp-capping with MTA, Miles and colleagues<sup>105</sup> reported on caries-exposed permanent teeth with closed apex. Overall, the one-year pulp survival was 68%, while the two-year survival rate was 56%. A recent study<sup>87</sup> showed that MTA and calcium hydroxide had a successful outcome of 78% and 60%, respectively. Teeth that were permanently restored within 2 days after being capped had a better prognosis, and there was no difference between mechanical and caries pulp exposure<sup>106</sup>. Regarding caries-exposed pulp with an open apex in young immature tooth, MTA showed high clinical success in both primary<sup>107</sup> and permanent teeth<sup>74,108</sup> in periods ranging from six months to four years.

## 2) Modified MTAs and MTA-like materials

Some modified MTAs overcoming the drawbacks of the original MTA are available, and most of them aimed to shorten setting time by modifying the composition or particle size of the powder. In Angelus White MTA (setting time, 15 min), calcium sulfate was removed and calcium oxide was added to tricalcium silicate, dicalcium silicate, tricalcium aluminate and bismuth oxide<sup>109</sup>. In MM-MTA, calcium carbonate was added; in Tech BioSeal MTA, calcium chloride and montmorillonite were added; and the powder in MTA Plus was more finely ground.

MTA-like materials were marketed after 2006. They are not composed of Portland cement, which is manufactured from minerals of natural origin, but consist of synthetic calcium silicates as the main components and are aluminum-free. The difference in origin of calcium silicates is clearly demonstrated in the release of metal ions from the set materials<sup>110</sup>. In Angelus MTA and MM-MTA, which are based on Portland cement, a large amount of aluminum and trace amounts of arsenic, beryllium, cadmium and chromium were detected, but in DiaRoot Bioaggregate (DiaDent Group International, Cheongju-si, Korea), based on

synthetic calcium silicates, no metals were detected except a trace amount of aluminum.

BioAggregate, marketed in 2006, consists of tricalcium silicate, dicalcium silicate, tantalum pentoxide (radiopacifier), calcium phosphate monobasic (calcium dihydrogen phosphate) and amorphous silicon oxide. Calcium phosphate reacts with part of the calcium hydroxide produced from setting (hydrating) calcium silicates, and during the reaction, hydroxyapatite and water are formed. The water thus produced contributes to the hydration reaction speed. Silicon oxide also reacts with calcium hydroxide by the so-called pozzolanic reaction and thus contributes to setting time. The setting time is within 4 h at a normal optimal powder/liquid ratio (1 g/0.38 mL water). The antibacterial effect was reported to be similar to Dycal and inferior to zinc oxide/eugenol cement<sup>111</sup>.

Biodentine (Septodont, Lancaster, PA, USA), launched in 2009, contains tricalcium silicate, calcium carbonate and oxide and zirconium oxide (radiopacifier) in the powder, which is mixed with calcium chloride solution containing modified polycarboxylate instead of water. Both substances in the liquid contribute to shortened setting times (from 10 to 12 min). Calcium chloride accelerates the hydration reaction, and polycarboxylate reduces the amount of water required for mixing by providing proper consistency, which also contributes to easy handling of the mixture. Calcium carbonate in the powder is expected to act as a nucleation site in the hydrating mass, enhancing the hydration and leading to faster setting. Finer particles in the powder with larger specific surface areas can also contribute to short setting time: the specific surface area of Biodentine was reported to be about 2.8-fold compared with that of MTA Angelus White<sup>109</sup>. Biodentine was reported to have efficacy similar to that of MTA in direct capping over mechanically exposed molar pulps. Complete dentinal bridge formation, an absence of inflammatory pulp response and layers of well-arranged odontoblasts and odontoblast-like cells were observed after 6 weeks<sup>112</sup>.

EndoSequence BC RRM (Brasseler USA, Savannah, GA, USA), introduced in 2009, includes tricalcium silicate, dicalcium silicate, tantalum pentoxide, zirconium oxide, calcium dihydrogen phosphate, calcium hydroxide and thickening agent and is used as a premixed-syringeable paste or putty without being mixed with water. Recently, in 2014, BC RRM-Fast Set Putty has been launched, which is made with a fast-set formula and equipped with a syringe delivery system. In this material, water required to hydrate calcium silicates depends on the presence of a natural source in dentin. The calcium silicates in the powder hydrate to produce a calcium silicate hydrate gel and calcium hydroxide. The calcium hydroxide reacts with the phosphate ions to precipitate hydroxyapatite and water. The water continues to react with the calcium silicates to precipitate additional gel-like calcium silicate hydrate. The water supplied through this reaction is an important factor in controlling the hydration rate and the setting time. Setting time is ~2 h for RRM and 20 min for BC RRM-Fast

Set Putty, according to the manufacturer. However, this appears questionable because the experiment studying the effect of the addition of water to the material showed a tendency for the initial setting time to increase (from about 75 h to 110 h) and the final setting time to decrease (from about 240 h to 170 h) when increasing amounts of water were added (from 1% to 9%)<sup>113</sup>. The largest particle size of the powder was 0.35  $\mu\text{m}$ , with approximately 50% of the particles being nano ( $1 \times 10^{-3}$   $\mu\text{m}$ ) in size<sup>114</sup>. This material was shown to have cytotoxicity levels similar to those of ProRoot MTA and MTA Angelus<sup>114</sup>. BC RRM putty has similar *in vitro* biocompatibility to MTA<sup>115</sup>. It had similar results compared with MTA when used as pulp-capping agents<sup>116</sup> and induced the proliferation of dental pulp cells and the formation of reparative dentin bridge<sup>117</sup>.

## 2. Resin-modified MTA cement

TheraCal LC (Bisco, Schaumburg, IL, USA) is a light-curing, resin-modified calcium-silicate-filled single paste, containing calcium oxide, calcium silicate particles (type III Portland cement), strontium glass, fumed silica, barium sulphate, barium zirconate and resin consisting of Bis-GMA and polyethylene glycol dimethacrylate<sup>118</sup>. The formation and leaching of calcium hydroxide were shown to be negligible, and little or no hydration was exhibited<sup>118</sup>. The inflammatory response was more intense than with MTA Angelus, and this material did not stimulate mineralization<sup>119</sup>.

## Resin-based cements

### 1. Composite and MMA-based cements

As described above, at present, the sealing ability of the materials based on inorganic compounds used as the clinical standard needs further improvement, and adhesive resins should be helpful in this regard. The effectiveness of adhesives has been demonstrated *in vitro* and *in vivo*. A bonded coronal seal of either core paste (composite resin build-up material) and Tenure adhesives, or amalgam and Panavia, was reported to result in virtually no penetration of the India ink in which the teeth had been immersed for 10 days<sup>120</sup>.

Cox *et al.*<sup>121</sup> investigated the effect on pulp of calcium hydroxide capping and restoration with amalgam for cavities with exposed pulps in monkeys. Half of those pulps showed complete healing, and the remainder presented pulp inflammation of severity varying from localized low-grade accumulations of mononuclear leukocytes to extensive breakdown of the pulp tissue with abscess formation and necrosis after 1 and 2 years. This study demonstrated that recurring pulp inflammation was associated with bacterial contamination and implied the need for effective sealing of the exposure site to prevent marginal leakage of bacteria. Although a dentin bridge was formed by calcium hydroxide, it was reported that the bridge was heterogeneous and contained tunnel defects<sup>38</sup>. MTA was also reported to form tunnel defects<sup>59,122</sup>.

For effective tooth sealing, adhesive resins should be helpful. In animal studies<sup>123-126</sup>, successful pulp

healing and dentin bridge formations have been reported when adhesive resins were used for direct pulp-capping. However, in the literature, including several histology-based reports of direct pulp-capping for mechanically exposed human teeth, the situation is different. Bonding agents such as All Bond 2 (Bisco)<sup>127</sup>, Clearfil Liner Bond 2 (Kuraray, Tokyo, Japan)<sup>128</sup>, Scotch Bond Multi-Purpose (3M ESPE)<sup>129</sup>, Single Bond (3M ESPE)<sup>130</sup> and composite resin (Z100) (3M ESPE) were applied to the pulp for periods ranging from 2 to 10 months. Calcium-hydroxide-based cement (Dycal) was used as a control in all cases. These reports concluded that Dycal is better than the resin systems, possibly due to the effect of residual monomer on the vital pulp.

Monomer cytotoxicity can affect vital pulp in the short term, before setting, or in the long term, after setting<sup>131–133</sup>. Before setting, the cytotoxicity of the monomer itself will affect the pulp, while after setting, the effect of residual monomer contained in the set resin will depend on the amount and elution kinetics of the monomer.

Cytotoxicity testing of 39 monomers used in dental materials revealed that methyl methacrylate (MMA) was least cytotoxic<sup>134</sup>. Other reports indicate similarly the lowest cytotoxicity for MMA<sup>135,136</sup>. Because of the low toxicity of MMA, MMA-based resin has long been successfully, and widely used for bone cements to anchor artificial joints in orthopedic surgery.

The inferior outcome of the resin systems used for direct pulp-capping compared with Dycal may be due to the high cytotoxicity of the monomers used in those systems. In terms of monomer cytotoxicity, the MMA-based resin should be the best option for a pulp-capping resin. The minimal effect of MMA on pulp tissue has been reported. Pulp tissues removed from rabbit incisors were immersed in MMA for 1 min. The MMA-immersed and the untreated control pulp tissues were autotransplanted beneath the kidney capsule. The MMA-immersed pulp and the untreated control pulp tissue were positive for osteocalcin and presented osteodentin formation at 7 days. This suggested that MMA did not inhibit the osteogenic activity of pulp tissue<sup>137</sup>.

An *in vivo* comparison of MMA-based resins with composite resin has been published by Tronstad and Spångberg<sup>138</sup>. The pulp responses to Bis-GMA-based composite resin (Concise) (3M, St. Paul, MN, USA) and MMA-based resins initiated by sulfinic acid (Sevriton, de Trey, Zürich, Switzerland) or tributylborane (TBB) (Polycap, Ivoclar Vivadent) in deep Class V cavities in monkeys were compared. After 8 days, the degrees and percentages of responses were slight, moderate and severe in this order: 30%, 50% and 20% for Concise; 30%, 20% and 50% for Sevriton; and 75%, 25% and 0% for Polycap, respectively. No severe response was seen in Polycap. Overall, the severity of the pulp response was lowest for Polycap compared with that of Concise and Sevriton. The remarkable difference in the responses between Sevriton and Polycap is noteworthy because both resins are composed basically of MMA monomer,

but the polymerization initiator is different. This suggests that the pulp response to resins is significantly affected by not only the type of resin monomer but also by the polymerization initiator (catalyst). In the paper cited above<sup>138</sup>, no material information on the resins was provided. From the literature, the catalyst of Sevriton is known to be sulfinic acid<sup>139</sup>, but no information on Polycap is available. However, the statement in the discussion citing two papers<sup>140,141</sup> clearly suggests that Polycap was actually the same material as Palakav (Firma Kulzer, Hanau, Germany) and its premarketing material F1, which were MMA-based resins initiated by TBB (MMA-TBB resin). It was reported that Polycap is a joint product of Vivadent and Kulzer<sup>142</sup>.

## 2. MMA-TBB resin cement

A successful clinical trial of the MMA-TBB resin was reported in 1968, indicating a minimal pulp damage histologically after 9–12 months in unlined cavities of vital teeth by filling F1 (MMA-TBB resin)<sup>143,144</sup>. A similar favorable clinical result was reported in 1976. No pulpal necrosis or partial pulpitis could be observed after 2–35 months by filling Polycap (MMA-TBB resin) in unlined cavities of vital teeth<sup>142</sup>. Thus, MMA-TBB resin seems promising as a pulp-capping resin. Christensen has referred to 4-META bonding agent, which is the MMA-TBB resin containing 4-[2-(methacryloyloxy)-ethoxycarbonyl]phthalic anhydride (4-META), as a clinically successful bonding agent for pulp-capping<sup>145</sup>. In Japan, it has been used for direct capping with clinical success by practitioners experienced with the resin. Although clinical reports are scarce<sup>146–150</sup>, several *in vitro* and *in vivo* studies supporting clinical success have been published.

Cellular activities of rat dental pulp cells cultured on 4-META/MMA-TBB resin (4-META resin for short) (SuperBond, Sun Medical, Moriyama, Japan) were comparable to control plastic plates, suggesting that the resin did not induce cytotoxic responses<sup>151</sup>. Cell viability of 4-META resin was reported to increase from 66% for fresh material to 100% for the set resin. This suggests that cytotoxicity of the resin was significantly reduced during the course of setting<sup>152</sup>.

Evident dentin bridge formation was reported on the surgically exposed dental pulp in germ-free rats after application of 4-META resin<sup>153</sup>. Favorable periapical tissue healing in the rat molar after retrofilling with 4-META resin was reported that the resin produced the least severe inflammatory reaction and the greatest amount of new bone, and thus fostered the natural regeneration of the periapical tissue<sup>154</sup>. Investigation of nerve regeneration and proliferative activity in amputated pulp tissue of dogs after the application of 4-META resin or calcium hydroxide revealed that wound-healing of the exposed pulp surface occurred for the resin in a manner similar to that with calcium hydroxide<sup>155</sup>.

The best support for clinical success of the resin is provided by Inoue *et al.*, who conducted comprehensive *in vitro* and *in vivo* studies of the resin. Their works have



also been summarized as review articles<sup>156,157</sup>. Important points from their studies will be referred to below.

Cytotoxicity testing with L-929 cells by the Millipore filter method was carried out by the placement of 4-META resin at 1, 5 and 10 min, and 1 and 24 h after the resin components were mixed on the filter. Bis-GMA resin (Panavia) (Kuraray) was also tested as a control. 4-META resin showed only slight toxic effects up to 10 min, at which time the resin was fully cured. However, the Bis-GMA resin showed moderate toxic effects up to 60 min<sup>158</sup>. A cell proliferation test was performed on completely polymerized 4-META and Bis-GMA resins for up to 4 days. The results showed that the proliferation rate of the cells on 4-META resin was slower than that on the control (culture dish), but the cells remained viable over the test periods. The polymerized 4-META resin appeared to cause almost no cytotoxic damage to the cells. No cells were found on the Bis-GMA resin at any experimental period<sup>158</sup>.

The 4-META resin was polymerized directly onto human pulp. The tooth with the polymerized resin was treated with 36% hydrochloric acid to remove the pulp tissue underlying the resin and then treated with acetone to remove the polymerized resin. After these treatments, a thin layer of film was obtained, which the authors called the residual soft-tissue hybrid layer (STHL). SEM and TEM observation studies showed the presence of collagen fibers, cells and capillaries in the STHL. Moreover, XPS analysis showed the presence of nitrogen and sulfur on the STHL, indicating that this layer contained pulp tissue components<sup>156</sup>. These results clearly demonstrated graft polymerization of MMA to pulp tissue, which means that poly(methyl methacrylate) bonds chemically to pulp tissue. STHL is undoubtedly a graft polymer, although the authors did not refer to the formation of graft polymer. Generally, graft polymer is composed of a main backbone polymer to which different type of the branch polymers is chemically connected through covalent bonds.

*In vivo* testing in humans was performed in premolars. After preparation of an occlusal cavity, the pulp was exposed and the cavity was filled with 4-META resin. The teeth were extracted at 7 to 294 days and observed histologically. Patients complained of neither pain nor hypersensitivity. The *in vivo* studies showed that: (1) only slight inflammatory cell infiltration was found in some cases in the early stage; (2) dentin bridge formation occurred in half of the experiment cases; and (3) macrophages appeared in some cases in the later stage. Based on these results, the authors concluded that 4-META resin could be used to conserve pulp because the resin had no cytotoxic effects on pulp and maintained a biological seal, which was achieved by the STHL described above. Thus, they stated that STHL might have a protective function on exposed pulp, much like that of a dentin bridge, and therefore might be called an “artificial dentin bridge”<sup>156,159</sup>. Figure 1 illustrates the formation of a soft-tissue hybrid layer (STHL)<sup>156</sup> or “artificial dentin bridge”<sup>156</sup> in direct pulp-capping with MMA-TBB resin by graft polymerization and interfacial

initiation of a polymerization mechanism<sup>160</sup>.

There are four probable reasons for the success of MMA-TBB resin: (1) MMA is least cytotoxic among the monomers used in dentistry<sup>134-136</sup>; (2) TBB initiator reduces the residual MMA after setting with time<sup>160,161</sup>; (3) TBB has the capacity to induce interfacial polymerization of MMA at the dentin interface<sup>160,162</sup>; and (4) TBB causes graft polymerization of MMA onto dentin collagen to produce a graft polymer composed of collagen and MMA polymer<sup>140,160</sup>.

Reasons (1) and (2) appear to correlate with the results of the studies by Inoue *et al.*<sup>158,159</sup>, whose results showed that (a) 4-META resin demonstrated cytotoxicity *in vitro* only at the early period after the start of setting of the resin, and (b) the resin caused slight inflammatory cell infiltration in the early stage *in vivo*. It was reported that residual MMA monomer decreased from 8.15% to 1.96%, 0.84% and 0.48% at 30 min, 24 h, 1 and 4 weeks after the start of setting of MMA-TBB resin<sup>161</sup>. This significant decrease of the residual monomer with time can be correlated with cell responses *in vitro* and *in vivo* as described above. Moreover, dentin bridge formation in the human study was not always observed in all experimental cases, but occurred in half of the cases<sup>156,159</sup>. The absence of dentin bridge formation in half of the cases may be correlated to a weak inflammatory response caused by 4-META resin. In pulp repair, it is suggested that the initial mild inflammatory reaction as caused by calcium hydroxide application is a prerequisite for tissue repair, which would not occur if this essential step was omitted<sup>24</sup>. Therefore, an inflammatory reaction caused by the resin may sometimes fall below the level of mild reaction.

The effects of reasons (3) and (4) enable reliable sealing of the interface to occur. These characteristics of TBB in polymerization will be correlated with favorable dental tissue responses in the filling of MMA-TBB resin in deep unlined cavities in clinical trials<sup>143,144</sup> and in animal studies, as described above. The comparison of polymerization behavior in a cavity model initiated by conventional benzoyl peroxide (BPO)/amine and TBB initiators is illustrated in Fig. 1. The polymerization of conventional restorative resins starts from the resin side, and the effect of polymerization shrinkage occurs between the dentin and resin. However, according to the report by Imai *et al.*<sup>162</sup>, the polymerization of MMA-TBB resin starts from the dentin interface. The dentin interface is thus sealed tightly with the resin, in cooperation with excellent dentin bonding property of the resin through the graft polymer formation mechanism. While the shrinkage of resins creates space in conventional resin, MMA-TBB produces minimum space, which leads to less leakage compared with that of conventional resins. The apical sealing ability of MMA-TBB resin was reported to be significantly better compared with that of gutta-percha/sealer and root canal filling of the resin formed resin tags in dentinal tubules<sup>163</sup>. This excellent seal helps protect against bacterial contamination, the importance of which in pulp-capping was suggested by Cox *et al.*<sup>121</sup>



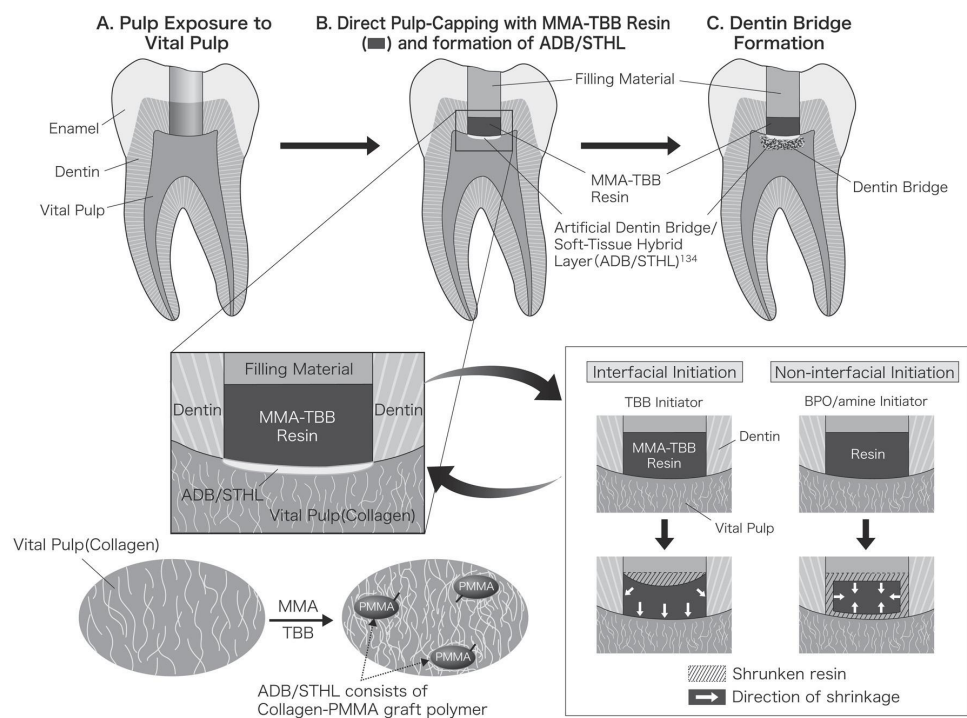


Fig. 1 Formation of Artificial Dentin Bridge (ADB) or Soft-Tissue Hybrid Layer (STHL) in direct pulp-capping with MMA-TBB resin by graft polymerization and interfacial initiation of polymerization mechanism.

A: Exposure of vital pulp. B: Direct pulp-capping with MMA-TBB resin and formation of ADB/STHL, which consists of collagen-PMMA graft polymer. Interfacial initiation of polymerization begins on the dentin side, to which the resin is attracted during polymerization, leading to elimination of gap formation between dentin and the resin. C: Dentin bridge formation, which occurred in half of the experiments<sup>15,6)</sup>.

Generally pulp capping should be performed in cases with no clinical symptoms and with normal clinical examination. If pulp capping need to be performed in pulp that is suspected of having limited inflammation, such as pulp exposure during or after removing caries, calcium hydroxide/MTA would be the choice instead of MMA-TBB resin. Since MMA-TBB resin does not possess bactericidal action, MMA-TBB resin will be used clinically only for uninfected pulp.

#### FUTURE CONSIDERATIONS FOR PULP-CAPPING MATERIAL

The success rate of direct pulp-capping is inferior to that of pulpectomy. Current materials lack effectiveness mainly because of leakage at the interface between the dentin and pulp-capping material as well as restorative material. For the development of future pulp-capping materials, the use of ECM may be considered an option, as suggested by Goldberg *et al.*<sup>24,27)</sup>. The other is the application of high-quality dentin adhesive material with the capability of initiating interfacial polymerization for restorative material over the direct pulp-capping material. The well-sealed restoration will prevent

leakage and enhance long-term success. In this respect, MMA-TBB resin is useful not only for restoration but also for direct pulp-capping in the future. The reason is as follows: While it takes at least one week for calcium hydroxide and MTA to form a natural dentin bridge, one day is enough for MMA-TBB resin to form an “artificial dentin bridge”. Rapid formation of a pulp-protective barrier against bacterial contamination should be desirable to minimize the damage to the pulp. Moreover, the former natural bridges sometimes have tunnel defects, but the latter impermeable “artificial bridge” has no such defect. MTA/MTA related materials and MMA-TBB resin have the advantages of anti-bacterial effects and rapid formation of a pulp-protective barrier, respectively. Therefore, in the future, both materials may be chosen depending on each clinical case for direct pulp-capping. The addition of anti-bacterial substrates to the resin may plus another advantage. It is expected that MMA-TBB resin will be widely accepted worldwide in clinical practice in the future, although only limited numbers of clinicians in Japan are using it. For the resin to be widely used, it must receive official approval as a direct-capping material, because the present commercial resin is approved for restorations, and direct

pulp-capping is not included in the indications for use. Therefore, currently, the resin is used at the dentist's discretion.

## REFERENCES

- 1) Bergenholtz G, Mjör IA, Cotton WR, Hanks CT, Kim S, Torneck CD, Trowbridge HO. The biology of dentin and pulp. Consensus report. *J Dent Res* 1985; 64: 631-633.
- 2) Couve E. Ultrastructural changes during the life cycle of human odontoblasts. *Arch Oral Biol* 1986; 31: 643-651.
- 3) Pashley DH. Dynamics of the pulpo-dentin complex. *Crit Rev Oral Biol Med* 1996; 7: 104-133.
- 4) Zander HA, Glass RL. The healing of phenolized pulp exposures. *Oral Surg Oral Med Oral Pathol* 1949; 2: 803-810.
- 5) Bergenholtz G. Advances since the paper by Zander and Glass (1949) on the pursuit of healing methods for pulpal exposures: historical perspectives. *Oral Surg Oral Med Oral Pathol Oral Radiol Endod* 2005; 100: S102-S108.
- 6) ADA. 2005-2006 Survey of dental services rendered and distribution of dentists in the United States by region and state. Chicago: American Dental Association, Survey Center.
- 7) Cheung GS. Endodontic failures —changing the approach. *Int Dent J* 1996; 46: 131-138.
- 8) Figdor D. Apical periodontitis: a very prevalent problem. *Oral Surg Oral Med Oral Pathol Oral Radiol Endod* 2002; 94: 651-652.
- 9) Stanley HR. Criteria for standardizing and increasing credibility of direct pulp capping studies. *Am J Dent* 1998; 11 Spec No: S17-S34.
- 10) Bender IB. Reversible and irreversible painful pulpitis: diagnosis and treatment. *Aust Endod J* 2000; 26: 10-14.
- 11) Dammaschke T. The history of direct pulp capping. *J History Dent* 2008; 56: 9-23.
- 12) Hasheminia SM, Feizi G, Razavi SM, Feizianfard M, Gutknecht N, Mir M. A comparative study of three treatment methods of direct pulp capping in canine teeth of cats: a histologic evaluation. *Lasers Med Sci* 2010; 25: 9-15.
- 13) Hermann B. Calciumhydroxyd als Mittel zum Behandeln und Füllen von Zahnwurzelkanälen Würzburg, Germany: Faculty of Medicine, University of Würzburg; 1920.
- 14) Hermann B. Dentinobliteration der Wurzelkanäle nach Behandlung mit Calcium. *Zahnärztl Rundschau* 1930; 39: 888-898.
- 15) Stuart KG, Miller CH, Brown CE Jr, Newton CW. The comparative antimicrobial effect of calcium hydroxide. *Oral Surg Oral Med Oral Pathol* 1991; 72: 101-104.
- 16) Cavalcanti BN, Rode SM, Marques MM. Cytotoxicity of substances leached or dissolved from pulp capping materials. *Int Endod J* 2005; 38: 505-509.
- 17) Dougherty E, inventor. Dental cement material patent United States Patent & Trademark Office 3,047,408. 1962.
- 18) Sawusch R. Dycal capping of exposed pulps in primary teeth. *J Dent Child* 1963; 30: 141-149.
- 19) Paterson RC. Corticosteroids and the exposed pulp. *Br Dent J* 1976; 140: 174-177.
- 20) Watts A, Paterson RC. The response of the mechanically exposed pulp to prednisolone and triamcinolone acetonide. *Int Endod J* 1988; 21: 9-16.
- 21) Rutherford RB, Spångberg L, Tucker M, Rueger D, Charette M. The time-course of the induction of reparative dentine formation in monkeys by recombinant human osteogenic protein-1. *Arch Oral Biol* 1994; 39: 833-838.
- 22) Tewari S. Assessment of coronal microleakage in intermediately restored endodontic access cavities. *Oral Surg Oral Med Oral Pathol Oral Radiol Endod* 2002; 93: 716-719.
- 23) Langeland K. Management of the inflamed pulp associated with deep carious lesion. *J Endod* 1981; 7: 169-181.
- 24) Goldberg M, Farges JC, Lacerda-Pinheiro S, Six N, Jegat N, Decup F, Septier D, Carrouel F, Durand S, Chaussain-Miller C, DenBesten P, Veis A, Poliard A. Inflammatory and immunological aspects of dental pulp repair. *Pharmacol Res* 2008; 58: 137-147.
- 25) Rutherford B, Fitzgerald M. A new biological approach to vital pulp therapy. *Crit Rev Oral Biol Med* 1995; 6: 218-229.
- 26) Hu CC, Zhang C, Qian Q, Tatum NB. Reparative dentin formation in rat molars after direct pulp capping with growth factors. *J Endod* 1998; 24: 744-751.
- 27) Goldberg M, Smith AJ. Cells and extracellular matrices of dentin and pulp: A biological basis for repair and tissue engineering. *Crit Rev Oral Biol Med* 2004; 15: 13-27.
- 28) Decup F, Six N, Palmier B, Buch D, Lasfargues JJ, Salih E, Goldberg M. Bone sialoprotein-induced reparative dentinogenesis in the pulp of rat's molar. *Clin Oral Investig* 2000; 4: 110-119.
- 29) Six N, Septier D, Chaussain-Miller C, Blacher R, DenBesten P, Goldberg M. Dentonin, a MEPE fragment, initiates pulp-healing response to injury. *J Dent Res* 2007; 86: 780-785.
- 30) Koike T, Polan MA, Izumikawa M, Saito T. Induction of reparative dentin formation on exposed dental pulp by dentin phosphophoryn/collagen composite. *BioMed Res Int* 2014; 2014: 745139.
- 31) Felton DA, Cox CF, Odom M, Kanoy BE. Pulpal response to chemically cured and experimental light-cured glass ionomer cavity liners. *J Prosthet Dent* 1991; 65: 704-712.
- 32) Tarim B, Hafez AA, Cox CF. Pulpal response to a resin-modified glass-ionomer material on nonexposed and exposed monkey pulps. *Quintessence Int* 1998; 29: 535-542.
- 33) Gaintantzopoulou MD, Willis GP, Kafrawy AH. Pulp reactions to light-cured glass ionomer cements. *Am J Dent* 1994; 7: 39-42.
- 34) do Nascimento AB, Fontana UF, Teixeira HM, Costa CA. Biocompatibility of a resin-modified glass-ionomer cement applied as pulp capping in human teeth. *Am J Dent* 2000; 13: 28-34.
- 35) Torabinejad M, White DJ, inventors. Tooth filling material and method of use. patent United States Patent & Trademark Office 5,415,547. 1995.
- 36) Aguilar P, Linsuwanont P. Vital pulp therapy in vital permanent teeth with cariously exposed pulp: a systematic review. *J Endod* 2011; 37: 581-587.
- 37) Schroder U. Effects of calcium hydroxide-containing pulp-capping agents on pulp cell migration, proliferation, and differentiation. *J Dent Res* 1985; 64: 541-548.
- 38) Cox CF, Subay RK, Ostro E, Suzuki S, Suzuki SH. Tunnel defects in dentin bridges: their formation following direct pulp capping. *Oper Dent* 1996; 21: 4-11.
- 39) Cox CF, Suzuki S. Re-evaluating pulp protection: calcium hydroxide liners vs. cohesive hybridization. *J Am Dent Assoc* 1994; 125: 823-831.
- 40) Taira Y, Shinkai K, Suzuki M, Kato C, Katoh Y. Direct pulp capping effect with experimentally developed adhesive resin systems containing reparative dentin-promoting agents on rat pulp: mixed amounts of additives and their effect on wound healing. *Odontology* 2011; 99: 135-147.
- 41) Hassan EH, Van Huysen G, Gilmore HW. Deep cavity preparation and the tooth pulp. *J Prosthet Dent* 1966; 16: 751-755.
- 42) Rowe AH. Reaction of the rat molar pulp to various materials. *Br Dent J* 1967; 122: 291-300.
- 43) Eleazer P, Bolanos O, Sinai I, Martin J, Seltzer S. The effect of unbound powdered materials on dog dental pulps. *J Endod* 1981; 7: 462-465.
- 44) Pereira JC, Brante CM, Berbert A, Mondelli J. Effect of calcium hydroxide in powder or in paste form on pulp-capping procedures: histopathologic and radiographic analysis in dog's

- pulp. *Oral Surg Oral Med Oral Pathol* 1980; 50: 176-186.
- 45) Weiss MB, Bjorvatn K. Pulp capping in deciduous and newly erupted permanent teeth of monkeys. *Oral Surg Oral Med Oral Pathol* 1970; 29: 769-775.
  - 46) Binnie WH, Rowe AH. A histological study of the periapical tissues of incompletely formed pulpless teeth filled with calcium hydroxide. *J Dent Res* 1973; 52: 1110-1116.
  - 47) Stanley HR, Pameijer CH. Dentistry's friend: calcium hydroxide. *Oper Dent* 1997; 22: 1-3.
  - 48) Mente J, Hufnagel S, Leo M, Michel A, Gehrig H, Panagidis D, Saure D, Pfefferle T. Treatment outcome of mineral trioxide aggregate or calcium hydroxide direct pulp capping: long-term results. *J Endod* 2014; 40: 1746-1751.
  - 49) Willershausen B, Willershausen I, Ross A, Velikonja S, Kasaj A, Blettner M. Retrospective study on direct pulp capping with calcium hydroxide. *Quintessence Int* 2011; 42: 165-171.
  - 50) Al-Hiyasat AS, Barrieshi-Nusair KM, Al-Omari MA. The radiographic outcomes of direct pulp-capping procedures performed by dental students: a retrospective study. *J Am Dent Assoc* 2006; 137: 1699-1705.
  - 51) Barthel CR, Rosenkranz B, Leuenberg A, Roulet JF. Pulp capping of carious exposures: treatment outcome after 5 and 10 years: a retrospective study. *J Endod* 2000; 26: 525-528.
  - 52) Sjögren U, Figdor D, Persson S, Sundqvist G. Influence of infection at the time of root filling on the outcome of endodontic treatment of teeth with apical periodontitis. *Int Endod J* 1997; 30: 297-306.
  - 53) Imura N, Pinheiro ET, Gomes BP, Zaia AA, Ferraz CC, Souza-Filho FJ. The outcome of endodontic treatment: a retrospective study of 2000 cases performed by a specialist. *J Endod* 2007; 33: 1278-1282.
  - 54) Roberts HW, Toth JM, Berzins DW, Charlton DG. Mineral trioxide aggregate material use in endodontic treatment: a review of the literature. *Dent Mater* 2008; 24: 149-164.
  - 55) Torabinejad M, Parirokh M. Mineral trioxide aggregate: a comprehensive literature review —Part II: leakage and biocompatibility investigations. *J Endod* 2010; 36: 190-202.
  - 56) Parirokh M, Torabinejad M. Mineral trioxide aggregate: a comprehensive literature review —Part III: Clinical applications, drawbacks, and mechanism of action. *J Endod* 2010; 36: 400-413.
  - 57) Darvell BW, Wu RC. "MTA"-an Hydraulic Silicate Cement: review update and setting reaction. *Dent Mater* 2011; 27: 407-422.
  - 58) Ford T, Torabinejad M, Abedi H, Bakland L, Kariyawasam S. Using mineral trioxide aggregate as a pulp-capping material. *J Am Dent Assoc* 1996; 127: 1491-1494.
  - 59) Faraco IM Jr, Holland R. Response of the pulp of dogs to capping with mineral trioxide aggregate or a calcium hydroxide cement. *Dent Traumatol* 2001; 17: 163-166.
  - 60) Tziafas D, Pantelidou O, Alvanou A, Belibasakis G, Papadimitriou S. The dentinogenic effect of mineral trioxide aggregate (MTA) in short-term capping experiments. *Int Endod J* 2002; 35: 245-254.
  - 61) Aeinehchi M, Eslami B, Ghanbariha M, Saffar AS. Mineral trioxide aggregate (MTA) and calcium hydroxide as pulp-capping agents in human teeth: a preliminary report. *Int Endod J* 2003; 36: 225-231.
  - 62) Dominguez MS, Witherspoon DE, Gutmann JL, Opperman LA. Histological and scanning electron microscopy assessment of various vital pulp-therapy materials. *J Endod* 2003; 29: 324-333.
  - 63) Parirokh M, Asgary S, Eghbal MJ, Stowe S, Eslami B, Eskandarizade A, Shabahang S. A comparative study of white and grey mineral trioxide aggregate as pulp capping agents in dog's teeth. *Dent Traumatol* 2005; 21: 150-154.
  - 64) Parirokh M, Torabinejad M. Mineral trioxide aggregate: a comprehensive literature review —Part I: chemical, physical, and antibacterial properties. *J Endod* 2010; 36: 16-27.
  - 65) Torabinejad M, Hong CU, Pitt Ford TR, Kettering JD. Antibacterial effects of some root end filling materials. *J Endod* 1995; 21: 403-406.
  - 66) Estrela C, Bammann LL, Estrela CR, Silva RS, Pecora JD. Antimicrobial and chemical study of MTA, Portland cement, calcium hydroxide paste, Sealapex and Dycal. *Br Dent J* 2000; 11: 3-9.
  - 67) Miyagak DC, de Carvalho EM, Robazza CR, Chavasco JK, Levorato GL. In vitro evaluation of the antimicrobial activity of endodontic sealers. *Braz Oral Res* 2006; 20: 303-306.
  - 68) Tanomaru-Filho M, Tanomaru JM, Barros DB, Watanabe E, Ito IY. In vitro antimicrobial activity of endodontic sealers, MTA-based cements and Portland cement. *J Oral Sci* 2007; 49: 41-45.
  - 69) Asgary S, Kamrani FA. Antibacterial effects of five different root canal sealing materials. *J Oral Sci* 2008; 50: 469-474.
  - 70) Okiji T, Yoshiba K. Reparative dentinogenesis induced by mineral trioxide aggregate: a review from the biological and physicochemical points of view. *Int J Dent* 2009; 2009: 464280.
  - 71) Camilleri J, Montesin FE, Di Silvio L, Pitt Ford TR. The chemical constitution and biocompatibility of accelerated Portland cement for endodontic use. *Int Endod J* 2005; 38: 834-842.
  - 72) Santos AD, Moraes JC, Araujo EB, Yukimitu K, Valerio Filho WV. Physico-chemical properties of MTA and a novel experimental cement. *Int Endod J* 2005; 38: 443-447.
  - 73) Kogan P, He J, Glickman GN, Watanabe I. The effects of various additives on setting properties of MTA. *J Endod* 2006; 32: 569-572.
  - 74) Bogen G, Kim JS, Bakland LK. Direct pulp capping with mineral trioxide aggregate: an observational study. *J Am Dent Assoc* 2008; 139: 305-315.
  - 75) Jacobovitz M, de Lima RK. Treatment of inflammatory internal root resorption with mineral trioxide aggregate: a case report. *Int Endod J* 2008; 41: 905-912.
  - 76) Belobrov I, Parashos P. Treatment of tooth discoloration after the use of white mineral trioxide aggregate. *J Endod* 2011; 37: 1017-1020.
  - 77) Ioannidis K, Mistakidis I, Beltes P, Karagiannis V. Spectrophotometric analysis of coronal discoloration induced by grey and white MTA. *Int Endod J* 2013; 46: 137-144.
  - 78) Torabinejad M, Chivian N. Clinical applications of mineral trioxide aggregate. *J Endod* 1999; 25: 197-205.
  - 79) Chng HK, Islam I, Yap AU, Tong YW, Koh ET. Properties of a new root-end filling material. *J Endod* 2005; 31: 665-668.
  - 80) Lee YL, Lee BS, Lin FH, Yun Lin A, Lan WH, Lin CP. Effects of physiological environments on the hydration behavior of mineral trioxide aggregate. *Biomaterials* 2004; 25: 787-793.
  - 81) Komabayashi T, Spångberg LS. Comparative analysis of the particle size and shape of commercially available mineral trioxide aggregates and Portland cement: a study with a flow particle image analyzer. *J Endod* 2008; 34: 94-98.
  - 82) Camilleri J, Montesin FE, Brady K, Sweeney R, Curtis RV, Ford TR. The constitution of mineral trioxide aggregate. *Dent Mater* 2005; 21: 297-303.
  - 83) Asgary S, Parirokh M, Eghbal MJ, Stowe S, Brink F. A qualitative X-ray analysis of white and grey mineral trioxide aggregate using compositional imaging. *J Mater Sci Mater Med* 2006; 17: 187-191.
  - 84) Lenherr P, Allgayer N, Weiger R, Filippi A, Attin T, Krastl G. Tooth discoloration induced by endodontic materials: a laboratory study. *Int Endod J* 2012; 45: 942-949.
  - 85) Felman D, Parashos P. Coronal tooth discoloration and white mineral trioxide aggregate. *J Endod* 2013; 39: 484-487.
  - 86) Camilleri J. Color stability of white mineral trioxide aggregate in contact with hypochlorite solution. *J Endod* 2014; 40: 436-440.
  - 87) Valles M, Mercade M, Duran-Sindreu F, Bourdelande JL,



- Roig M. Influence of light and oxygen on the color stability of five calcium silicate-based materials. *J Endod* 2013; 39: 525-528.
- 88) Valles M, Mercade M, Duran-Sindreu F, Bourdelande JL, Roig M. Color stability of white mineral trioxide aggregate. *Clin Oral Investig* 2013; 17: 1155-1159.
- 89) Torabinejad M, Higa RK, McKendry DJ, Pitt Ford TR. Dye leakage of four root end filling materials: effects of blood contamination. *J Endod* 1994; 20: 159-163.
- 90) Agrabawi J. Sealing ability of amalgam, super EBA cement, and MTA when used as retrograde filling materials. *Br Dent J* 2000; 188: 266-268.
- 91) Pereira CL, Cenci MS, Demarco FF. Sealing ability of MTA, Super EBA, Vitremer and amalgam as root-end filling materials. *Braz Oral Res* 2004; 18: 317-321.
- 92) Adamo HL, Buruiana R, Schertzer L, Boylan RJ. A comparison of MTA, Super-EBA, composite and amalgam as root-end filling materials using a bacterial microleakage model. *Int Endod J* 1999; 32: 197-203.
- 93) Mangin C, Yesilsoy C, Nissan R, Stevens R. The comparative sealing ability of hydroxyapatite cement, mineral trioxide aggregate, and super ethoxybenzoic acid as root-end filling materials. *J Endod* 2003; 29: 261-264.
- 94) Wu MK, Kontakiotis EG, Wesselink PR. Long-term seal provided by some root-end filling materials. *J Endod* 1998; 24: 557-560.
- 95) Gondim E, Zaia AA, Gomes BP, Ferraz CC, Teixeira FB, Souza-Filho FJ. Investigation of the marginal adaptation of root-end filling materials in root-end cavities prepared with ultrasonic tips. *Int Endod J* 2003; 36: 491-499.
- 96) Jenkins S, Kulild J, Williams K, Lyons W, Lee C. Sealing ability of three materials in the orifice of root canal systems obturated with gutta-percha. *J Endod* 2006; 32: 225-227.
- 97) Nair PN, Duncan HF, Pitt Ford TR, Luder HU. Histological, ultrastructural and quantitative investigations on the response of healthy human pulps to experimental capping with mineral trioxide aggregate: a randomized controlled trial. *Int Endod J* 2008; 41: 128-150.
- 98) Ford TR, Torabinejad M, Abedi HR, Bakland LK, Kariyawasam SP. Using mineral trioxide aggregate as a pulp-capping material. *J Am Dent Assoc* 1996; 127: 1491-1494.
- 99) Briso AL, Rahal V, Mestreneur SR, Dezan Junior E. Biological response of pulps submitted to different capping materials. *Braz Oral Res* 2006; 20: 219-225.
- 100) Asgary S, Eghbal MJ, Parirokh M, Ghanavati F, Rahimi H. A comparative study of histologic response to different pulp capping materials and a novel endodontic cement. *Oral Surg Oral Med Oral Pathol Oral Radiol Endod* 2008; 106: 609-614.
- 101) de Souza Costa CA, Duarte PT, de Souza PP, Giro EM, Hebling J. Cytotoxic effects and pulpal response caused by a mineral trioxide aggregate formulation and calcium hydroxide. *Am J Dent* 2008; 21: 255-261.
- 102) Simon S, Cooper P, Smith A, Picard B, Ifi CN, Berdal A. Evaluation of a new laboratory model for pulp healing: preliminary study. *Int Endod J* 2008; 41: 781-790.
- 103) Chacko V, Kurikose S. Human pulpal response to mineral trioxide aggregate (MTA): a histologic study. *J Clin Pediatr Dent* 2006; 30: 203-209.
- 104) Min KS, Park HJ, Lee SK, Park SH, Hong CU, Kim HW, Lee HH, Kim EC. Effect of mineral trioxide aggregate on dentin bridge formation and expression of dentin sialoprotein and heme oxygenase-1 in human dental pulp. *J Endod* 2008; 34: 666-670.
- 105) Miles JP, Gluskin AH, Chambers D, Peters OA. Pulp capping with mineral trioxide aggregate (MTA): a retrospective analysis of carious pulp exposures treated by undergraduate dental students. *Oper Dent* 2010; 35: 20-28.
- 106) Mente J, Geletneky B, Ohle M, Koch MJ, Friedrich Ding PG, Wolff D, Dreyhaupt J, Martin N, Staehle HJ, Pfefferle T. Mineral trioxide aggregate or calcium hydroxide direct pulp capping: an analysis of the clinical treatment outcome. *J Endod* 2010; 36: 806-813.
- 107) Caicedo R, Abbott PV, Alongi DJ, Alarcon MY. Clinical, radiographic and histological analysis of the effects of mineral trioxide aggregate used in direct pulp capping and pulpotomies of primary teeth. *Aust Dent J* 2006; 51: 297-305.
- 108) Farsi N, Alamoudi N, Balto K, Al Mushayt A. Clinical assessment of mineral trioxide aggregate (MTA) as direct pulp capping in young permanent teeth. *J Clin Pediatr Dent* 2006; 31: 72-76.
- 109) Camilleri J, Sorrentino F, Damidot D. Investigation of the hydration and bioactivity of radiopacified tricalcium silicate cement, Biodentine and MTA Angelus. *Dent Mater* 2013; 29: 580-593.
- 110) Kum KY, Kim EC, Yoo YJ, Zhu Q, Safavi K, Bae KS, Chang SW. Trace metal contents of three tricalcium silicate materials: MTA Angelus, Micro Mega MTA and Bioaggregate. *Int Endod J* 2014; 47: 704-710.
- 111) Yalcin M, Arslan U, Dundar A. Evaluation of antibacterial effects of pulp capping agents with direct contact test method. *Eur J Dent* 2014; 8: 95-99.
- 112) Nowicka A, Lipski M, Parafiniuk M, Sporniak-Tutak K, Lichota D, Kosierkiewicz A, Kaczmarek W, Buczkowska-Radlińska J. Response of human dental pulp capped with biodentine and mineral trioxide aggregate. *J Endod* 2013; 39: 743-747.
- 113) Loushine BA, Bryan TE, Looney SW, Gillen BM, Loushine RJ, Weller RN, Pashley DH, Tay FR. Setting properties and cytotoxicity evaluation of a premixed bioceramic root canal sealer. *J Endod* 2011; 37: 673-677.
- 114) Damas BA, Wheeler MA, Bringas JS, Hoen MM. Cytotoxicity comparison of mineral trioxide aggregates and EndoSequence bioceramic root repair materials. *J Endod* 2011; 37: 372-375.
- 115) Ma J, Shen Y, Stojicic S, Haapasalo M. Biocompatibility of two novel root repair materials. *J Endod* 2011; 37: 793-798.
- 116) Shi S, Bao ZF, Liu Y, Zhang DD, Chen X, Jiang LM, Zhong M. Comparison of in vivo dental pulp responses to capping with iRoot BP Plus and mineral trioxide aggregate. *Int Endod J* 2016; 49: 154-160.
- 117) Liu S, Wang S, Dong Y. Evaluation of a bioceramic as a pulp capping agent in vitro and in vivo. *J Endod* 2015; 41: 652-657.
- 118) Gandolfi MG, Siboni F, Prati C. Chemical-physical properties of TheraCal, a novel light-curable MTA-like material for pulp capping. *Int Endod J* 2012; 45: 571-579.
- 119) Gomes-Filho JE, de Faria MD, Bernabé PF, Nery MJ, Otoboni-Filho JA, Dezan-Júnior E, de Moraes Costa MM, Cannon M. Mineral trioxide aggregate but not light-cure mineral trioxide aggregate stimulated mineralization. *J Endod* 2008; 34: 62-65.
- 120) Davalou S, Gutmann JL, Nunn MH. Assessment of apical and coronal root canal seals using contemporary endodontic obturation and restorative materials and techniques. *Int Endod J* 1999; 32: 388-396.
- 121) Cox CF, Bergenholtz G, Heys DR, Syed SA, Fitzgerald M, Heys RJ. Pulp capping of dental pulp mechanically exposed to oral microflora: a 1-2 year observation of wound healing in the monkey. *J Oral Pathol* 1985; 14: 156-168.
- 122) Faraco Junior IM, Holland R. Histomorphological response of dogs' dental pulp capped with white mineral trioxide aggregate. *Braz Dent J* 2004; 15: 104-108.
- 123) Cox CF, Hafez AA, Akimoto N, Otsuki M, Suzuki S, Tarim B. Biocompatibility of primer, adhesive and resin composite systems on non-exposed and exposed pulps of non-human primate teeth. *Am J Dent* 1998; 11: S55-S63.
- 124) Tarim B, Hafez AA, Suzuki SH, Suzuki S, Cox CF.



- Biocompatibility of Optibond and XR-Bond adhesive systems in nonhuman primate teeth. *Int J Periodont Rest Dent* 1998; 18: 86-99.
- 125) Kitasako Y, Inokoshi S, Tagami J. Effects of direct resin pulp capping techniques on short-term response of mechanically exposed pulps. *J Dent* 1999; 27: 257-263.
- 126) Murray PE, Hafez AA, Smith AJ, Cox CF. Identification of hierarchical factors to guide clinical decision making for successful long-term pulp capping. *Quintessence Int* 2003; 34: 61-70.
- 127) Hebling J, Giro EM, Costa CA. Human pulp response after an adhesive system application in deep cavities. *J Dent* 1999; 27: 557-264.
- 128) de Souza Costa CA, Lopes do Nascimento AB, Teixeira HM, Fontana UF. Response of human pulps capped with a self-etching adhesive system. *Dent Mater* 2001; 17: 230-240.
- 129) Accorinte Mde L, Loguercio AD, Reis A, Muench A, de Araujo VC. Adverse effects of human pulps after direct pulp capping with the different components from a total-etch, three-step adhesive system. *Dent Mater* 2005; 21: 599-607.
- 130) Horsted-Bindslev P, Vilkinis V, Sidlauskas A. Direct capping of human pulps with a dentin bonding system or with calcium hydroxide cement. *Oral Surg Oral Med Oral Pathol Oral Radiol Endod* 2003; 96: 591-600.
- 131) Hanks CT, Strawn SE, Wataha JC, Craig RG. Cytotoxic effects of resin components on cultured mammalian fibroblasts. *J Dent Res* 1991; 70: 1450-1455.
- 132) Ratanasathien S, Wataha JC, Hanks CT, Dennison JB. Cytotoxic interactive effects of dentin bonding components on mouse fibroblasts. *J Dent Res* 1995; 74: 1602-1606.
- 133) Costa CA, Vaerten MA, Edwards CA, Hanks CT. Cytotoxic effects of current dental adhesive systems on immortalized odontoblast cell line MDPC-23. *Dent Mater* 1999; 15: 434-441.
- 134) Yoshii E. Cytotoxic effects of acrylates and methacrylates: relationships of monomer structures and cytotoxicity. *J Biomed Mater Res* 1997; 37: 517-524.
- 135) Imai Y, Watanabe M, Lee HE, Kojima K, Kadoma Y. Cytotoxicity of monomers used in dental resins. *Reports Inst Med Dent Eng* 1988; 22: 87-90.
- 136) Takeda S, Hashimoto Y, Miura Y, Kimura Y, Nakamura M. Cytotoxicity test of dental monomers using serum-free cell culture (in vitro). *J Jpn Dent Mater* 1993; 12: 613-619.
- 137) Inoue T, Miyakoshi S, Shimono M. The in vitro and in vivo influence of 4-META/MMA-TBB resin components on dental pulp tissues. *Adv Dent Res* 2001; 15: 101-104.
- 138) Tronstad L, Spångberg L. Biologic tests of a methyl methacrylate composite material. *Scand J Dent Res* 1974; 82: 93-98.
- 139) Brudevold F, Buonocore M, Wileman W. A report on a resin composition capable of bonding to human dentin surfaces. *J Dent Res* 1956; 35: 846-851.
- 140) Masuhara E. On the chemistry of a new adhesive plastic filling material. *Dtsch Zahnärztl Z* 1969; 24: 620-628.
- 141) Strassburg M, Knolle G. Dental fillings using Palakav. *Dtsch Zahnärztl Z* 1971; 26: 247-252.
- 142) Smékal VM, Cecava J, Hornová J, Buresová N. Reaction of the dental pulp to the filling material Polycap. *Stomatol DDR* 1976; 26: 648-653.
- 143) F Fischer CH, Grosz A, Masuhara E. 1st experiences with a new plastic filling material. *Dtsch Zahnärztl Z* 1968; 23: 209-212.
- 144) Herrmann D, Viohl J. Clinical studies on a new plastic filling material. *Dtsch Zahnärztl Z* 1968; 23: 212-217.
- 145) Christensen GJ. Pulp capping 1998. *J Am Dent Assoc* 1998; 129: 1297-1299.
- 146) Masaka N. The effective 4-META/MMA-TBB adhesive resin on the conservative pulp treatment. *Adhes Dent* 1992; 10: 9-16.
- 147) Katoh Y. Histopathological reaction of pulp in direct-capping of adhesive resinous materials. *J Dent Res* 1994; 73: 293.
- 148) Katoh Y, Kimura T, Inaba T. Clinical prognosis of pulp tissue direct-capped with adhesive resins. *J Dent Res* 1997; 76: 162.
- 149) Katoh Y, Kimura T, Inaba T. Long-term clinical prognosis of pulp tissue direct-capped with adhesive resin. *J Dent Res* 1998; 77: 636.
- 150) Morohoshi Y. Clinical application of 4-META/MMA-TBB adhesive resin on direct pulp capping. *Adhes Dent* 2002; 20: 260-261.
- 151) Imaizumi N, Kondo H, Ohya K, Kasugai S, Araki K, Kurosaki N. Effects of exposure to 4-META/MMA-TBB resin on pulp cell viability. *J Med Dent Sci* 2006; 53: 127-133.
- 152) Garza EG, Wadajkar A, Ahn C, Zhu Q, Opperman LA, Bellinger LL, Nguyen KT, Komabayashi T. Cytotoxicity evaluation of methacrylate-based resins for clinical endodontics in vitro. *J Oral Sci* 2012; 54: 213-217.
- 153) Inoue T, Shimono M. Repair dentinogenesis following transplantation into normal and germ-free animals. *Proc Finn Dent Soc* 1992; 88 Suppl 1: 183-194.
- 154) Maeda H, Hashiguchi I, Nakamuta H, Toriya Y, Wada N, Akamine A. Histological study of periapical tissue healing in the rat molar after retrofilling with various materials. *J Endod* 1999; 25: 38-42.
- 155) Nakamura M, Inoue T, Shimono M. Immunohistochemical study of dental pulp applied with 4-META/MMA-TBB adhesive resin after pulpotomy. *J Biomed Mater Res* 2000; 51: 241-248.
- 156) Inoue T, Miyakoshi S, Shimono M. Dentin pulp/adhesive resin interface: Biological view from basic science to clinic. In: Shimono M, Maeda T, Suda H, Takahashi K, editors. *Dentin/pulp complex*. Tokyo: Quintessence Publishing Co; 1996. p. 217-220.
- 157) Inoue T, Miyakoshi S. Influences of 4-META/MMA-TBB resin on pulp tissue. *Adhes Dent* 2014; 32: 36-62.
- 158) Morohoshi Y, Inoue T, Shimono M, Ichimura K, Masaka N. The effective 4-META/MMA-TBB adhesive resin on the conservative pulp treatment -2 An experimental study on cell reaction. *Adhes Dent* 1992; 10: 235-239.
- 159) Inoue T, Shimono M, Ichimura K, Masaka N, Miyakoshi S. 4-META/MMA-TBB resin and pulpal response. *Jpn J Endod Assoc* 1993; 14: 34-41.
- 160) Taira Y, Imai Y. Review of methyl methacrylate (MMA)/tributylborane (TBB)-initiated resin adhesive to dentin. *Dent Mater J* 2014; 33: 291-304.
- 161) Hirabayashi C, Imai Y. Studies on MMA-tBB resin. I. Comparison of TBB and other initiators in the polymerization of PMMA/MMA resin. *Dent Mater J* 2002; 21: 314-321.
- 162) Imai Y, Kadoma Y, Kojima K, Akimoto T, Ikakura K, Ohta T. Importance of polymerization initiator systems and interfacial initiation of polymerization in adhesive bonding of resin to dentin. *J Dent Res* 1991; 70: 1088-1091.
- 163) Imai Y, Komabayashi T. Properties of a new injectable type of root canal filling resin with adhesiveness to dentin. *J Endod* 2003; 29: 20-23.