

12-1-2015

# The Use Of Lasers For Direct Pulp Capping

Takashi Komabayashi

*The University of New England, [tkomabayashi@une.edu](mailto:tkomabayashi@une.edu)*

Arata Ebihara

*Tokyo Medical and Dental University*

Akira Aoki

*Tokyo Medical and Dental University*

Follow this and additional works at: [http://dune.une.edu/cdm\\_facpubs](http://dune.une.edu/cdm_facpubs)



Part of the [Dentistry Commons](#)

---

## Recommended Citation

Komabayashi, Takashi; Ebihara, Arata; and Aoki, Akira, "The Use Of Lasers For Direct Pulp Capping" (2015). *Dental Medicine Faculty Publications*. Paper 3.

[http://dune.une.edu/cdm\\_facpubs/3](http://dune.une.edu/cdm_facpubs/3)

This Article is brought to you for free and open access by the College of Dental Medicine at DUNE: DigitalUNE. It has been accepted for inclusion in Dental Medicine Faculty Publications by an authorized administrator of DUNE: DigitalUNE. For more information, please contact [bkenyon@une.edu](mailto:bkenyon@une.edu).

## Review

# The use of lasers for direct pulp capping

Takashi Komabayashi<sup>1)</sup>, Arata Ebihara<sup>2)</sup>, and Akira Aoki<sup>3)</sup>

<sup>1)</sup>College of Dental Medicine, University of New England, Portland, ME, USA

<sup>2)</sup>Department of Pulp Biology and Endodontics, Division of Oral Health Sciences,  
Graduate School of Medical and Dental Sciences, Tokyo Medical and Dental University, Tokyo, Japan

<sup>3)</sup>Department of Periodontology, Division of Bio-Matrix, Graduate School of Medical and Dental Sciences,  
Tokyo Medical and Dental University, Tokyo, Japan

(Received February 5, 2015; Accepted July 9, 2015)

**Abstract:** Direct pulp capping helps extend the life of a diseased tooth by maintaining tooth vitality. Nowadays, lasers are more frequently used during direct pulp capping in the clinic, but their use has not been previously reviewed. This review presents the basic properties of currently available lasers, scientific evidence on the effects of laser application on direct pulp capping, and future directions for this technology. An extensive literature search was conducted in various databases for articles published up to January 2015. Original *in vitro*, *in vivo*, and clinical studies, reviews, and book chapters published in English were included. Various laser systems have been increasingly and successfully applied in direct pulp capping. Lasers offer excellent characteristics in terms of hemostasis and decontamination for field preparation during direct pulp capping treatment; however, the sealing of exposed pulp with one of the dental materials, such as calcium hydroxide, mineral trioxide aggregates, and bonded composite resins, is still required after laser treatment. Clinicians should consider the characteristics of each wavelength, the emission mode, irradiation exposure time, power, type of laser tip, and the distance between the laser tip and the surface being irradiated.

(J Oral Sci 57, 277-286, 2015)

Keywords: direct pulp capping; lasers; CO<sub>2</sub> laser; Nd:YAG laser; diode laser; Er:YAG laser; Er,Cr:YSGG laser.

---

---

## Introduction

The three main causes of pulp exposure are caries, mechanical factors, and trauma (accidents). Direct pulp capping with a dental material, such as calcium hydroxide or calcium-hydroxide-based cements (1-11), mineral trioxide aggregate (12-21), and adhesive resins (22-28), is one way of treating the exposed vital pulp. This method is normally performed in case of mechanical or traumatic vital pulp exposure, as carious pulp exposure may be infected with bacteria from the carious lesion and may lead to pulp inflammation (29,30). This method involves two treatment steps: the first step involves preparation (often through hemostasis and decontamination) of the exposed pulp tissue and the surrounding dentin, whereas the second step consists of sealing the exposed pulp with one of the aforementioned dental materials so as to prevent bacterial penetration and achieve closure by means of calcified tissue formation. Direct pulp capping is advantageous for extending tooth life by maintaining tooth vitality as the direct pulp capping material facilitates the formation of reparative dentin from odontoblasts (31-33) and the maintenance of vital pulp (34-36). In particular, this technique may be helpful for the treatment of small carious lesions (37) or pulp exposures in young teeth with open apices (19) as it allows the remaining pulp to stay vital and supports continuous root development.

According to the American Association of Endo-

---

Correspondence to Dr. Takashi Komabayashi, College of Dental Medicine, University of New England, 716 Stevens Avenue, Portland, ME 04103, USA

E-mail: tkomabayashi@une.edu & icd38719@nifty.com

doi.org/10.2334/josnusd.57.277

DN/JST.JSTAGE/josnusd/57.277

**Table 1** Laser-tissue interaction of each wavelength

Laser type	Wavelength	Color	Soft tissue ablation	Coagulation	Carbonization	Hemostasis	Bacterial killing	Hard tissue ablation	Biostimulation
Diode; Gallium Aluminum Arsenide (GaAlAs)	670-830 nm	Red-infrared	+	++	+	++	+	-	++
Diode; Indium Gallium Arsenide (InGaAs)	980 nm	Infrared	+	++	+	++	+	-	++
Neodymium:YAG (Nd:YAG)	1,064 nm	Infrared	+	++	+	++	+	-	++
Erbium, chromium:YSGG (Er,Cr:YSGG)	2,780 nm	Infrared	++	+/-	+/-	+	+	++	+
Erbium:YAG (Er:YAG)	2,936 nm	Infrared	++	+/-	+/-	+	+	++	+
Carbon Dioxide (CO <sub>2</sub> )	10,600 nm	Infrared	++	+	++	++	+	-	+

dontists' (AAE) Guide to Clinical Endodontics, the indications for direct pulp capping are as follows: 1) occurrence of mechanical exposure of a clinically vital and asymptomatic pulp; 2) controlled bleeding at the exposure site; 3) possibility of direct contact of the capping material with the vital pulp tissue after exposure; 4) occurrence of exposure during dental dam isolation of the tooth; 5) maintenance of adequate seal of the coronal restoration; and 6) indication of a possible future endodontic treatment to the patient.

Recently, lasers have been used in various endodontic situations (38-43). Due to their excellent results for hemostasis and decontamination (40,44), lasers have grown in popularity for direct pulp capping in the clinic. However, the results of their use have not been previously reviewed. Therefore, this review presents the basic properties of currently available lasers, scientific evidences on the effects of laser application on direct pulp capping, and the future directions for this technology.

An extensive literature search was conducted in the PubMed/Medline, Web of Science, and Cochrane databases for publications up to January 2015 using keywords such as Lasers, Direct pulp capping, CO<sub>2</sub> laser, Nd:YAG laser, Diode laser, Er:YAG laser, and Er,Cr:YSGG laser. Additionally, a thorough manual search was performed based on the reference lists of relevant articles. Original *in vitro*, *in vivo*, and clinical studies, reviews, and book chapters in English language publications were included. Conference papers and abstracts were excluded.

### Historical background of the use of lasers in dentistry

LASER (Light Amplification by Stimulated Emission of Radiation) is essentially a man-made single-photon wavelength. Lasing is defined as a process wherein an atom is excited and stimulated to emit a photon before the process can occur spontaneously (44). This stimulated emission generates coherent (synchronous waves),

monochromatic (a single wavelength), and collimated forms (parallel rays) of light. Thus, lasers can effectively concentrate light energy on the target tissue at an energy level much lower than that of natural light. As a result of their photo-physical characteristics, laser irradiation offers strong ablation (44,45), hemostasis (44), detoxification (removal/ablation of toxic substances) (44), bactericidal effects (44,46), and biostimulatory effects on biological tissues (44,45) (Table 1).

Investigation of dental lasers began as early as the 1960s. The first laser, a ruby laser, was constructed in 1960 by Maiman (47). The first continuously generating laser was a low-powered helium and neon (He-Ne) laser developed by Javan et al. in 1961 (48), while an Nd:YAG laser was demonstrated for the first time by Geusic et al. at Bell Laboratories in 1964 (49). In 1965, Stern and Sognaes used the ruby laser to vaporize enamel and dentin (50). After these initial studies with ruby lasers, several other types of lasers appeared including argon (Ar), carbon dioxide (CO<sub>2</sub>), neodymium: yttrium-aluminum-garnet (Nd:YAG), erbium (Er):YAG, erbium, chromium: yttrium-scandium-gallium garnet (Er,Cr:YSGG) laser, and diode lasers (45). In 1971, Weichman and Johnson used a high-powered infrared (CO<sub>2</sub>) laser for the first time in endodontics to seal the apical foramen *in vitro* (51). Subsequently, attempts were made to seal the apical foramen using the help of the Nd:YAG laser (42,52). Of the available lasers, CO<sub>2</sub>, Nd:YAG, Er:YAG, and Er,Cr:YSGG are basically middle- to high-power lasers, while diode lasers have a wide energy emission range and can be used as low- or middle- to high-power lasers, depending on the energy level emitted.

### Basic properties of carbon dioxide (CO<sub>2</sub>), Nd:YAG, Er:YAG, Er,Cr:YSGG, and diode lasers

The characteristics of a laser depend on its wavelength. For example, the wavelength of a CO<sub>2</sub> laser is 10,600 nm

and is emitted in a continuous or gated pulsed mode. This is one of the most popular lasers for soft-tissue surgery and generally utilizes an articulated arm system with mirrors. Therefore, it is sometimes difficult to use this system in certain sections of the oral cavity such as root canals and periodontal pockets. However, the CO<sub>2</sub> laser wavelength is easily absorbed by water, which enhances its benefits for soft-tissue procedures. There is less carbonization or heat penetration on the surface when a substance being lased by CO<sub>2</sub> contains water, whereas carbonization and crack formations occur readily on the surface if it does not contain much water (e.g., dentin and enamel). An emission wavelength of 9,600 nm for the CO<sub>2</sub> laser is reported to be absorbed by hydroxyapatite crystals in enamel and dentin, causing tissue ablation, melting, and resolidification of tissues in the dental pulp in both humans (53) and dogs (54).

With a wavelength of 1,064 nm, the Nd:YAG laser can emit a high-energy free-running pulse. The infrared light of this laser is typically directed through optical fibers, the end of which is used for contact irradiation with a handpiece. The Nd:YAG laser originally operated in a continuous-wave mode, the current Nd:YAG laser systems have adopted a free-running pulsed mode (45,55). Several researchers have investigated various diameters of optical fibers used in medicine (56), and have manipulated their tips for effective irradiation (57-59). In dentistry, Nd:YAG lasers are indicated for soft-tissue surgeries such as gingivectomy, periodontal sulcular debridement, laser-assisted new attachment procedures (LANAP), frenectomy, biopsy, and coagulation of graft donor sites (57,60,61). These lasers are contra-indicated for peri-implant procedures as they easily cause melting of the titanium surfaces of dental implants (62). As the laser light of Nd:YAG lasers is selectively absorbed by dark colors, clinicians frequently paint a coating of black dye or paste on the target area before exposing it to the laser in order to enhance the absorption. The use of titanium dioxide (TiO<sub>2</sub>) pigment as an alternative to the black dye has also been historically studied (63).

The Er:YAG laser emits infrared light at a wavelength of 2,936 nm in a free-running pulsed mode. This laser utilizes fiber-optic or hollow wave-guiding delivery and a contact irradiation system with various kinds of contact tips mounted on a handpiece. Unlike the Nd:YAG and diode lasers, the wavelength of the Er:YAG laser is more easily absorbed by water compared to other currently available dental lasers due to its atomic resonance. The absorption coefficient of water under Er:YAG laser irradiation is theoretically 10 times higher than that with a CO<sub>2</sub> laser and 15,000–20,000 times higher than that

with an Nd:YAG laser (64). This laser energy is absorbed selectively by the water molecules and hydrous organic components in biological tissues, causing photothermal evaporation and, subsequently, thermal effects. In hard tissues, the water vapor production increases the tissues' internal pressure causing a "microexplosion" (65,66). The mechanical tissue collapses, resulting in "thermomechanical" or "photomechanical" ablation. In addition to water, hydroxyapatite can also absorb the Er:YAG laser relatively efficiently, a characteristic that is helpful for cutting hard tissues such as teeth (65,66) and bone (67). In contrast, the CO<sub>2</sub> laser is more highly absorbed by the phosphate mineral, but it cannot ablate hard tissue (44). Thus, the Er:YAG laser has an excellent capacity for ablating both soft and hard tissues with minimal thermal side-effects. It has been applied for bone surgery in oral surgery, dentistry, implant dentistry, and otolaryngology (68-71). The Erbium, Chromium: Yttrium-Scandium-Gallium Garnet (Er,Cr:YSGG) laser has a 2,780 nm wavelength, which is more highly absorbed by OH ions than by water molecules (72) and performs in a manner similar to the Er:YAG laser.

Diode lasers use nearly microscopic semiconductor chips to generate coherent light in a very small package. The mechanism of laser action is based on the differences in energy levels between the conduction and valence band electrons in these semiconductors. The diode laser wavelength is defined by the composition of the base compound. The most widely used lasers in this family are the gallium-aluminum-arsenide (GaAlAs) laser (810 nm) and indium-gallium-arsenide (InGaAs) laser (980 nm). Diode lasers operate in continuous and/or gated pulsed modes, and generally utilize fiber-optic delivery where the ends of the optical fibers are used for contact irradiation through a handpiece. There are only a few devices that contain a contact irradiation system with various kinds of contact tips mounted on a handpiece. Diode lasers are very effective in soft-tissue applications, offering excellent incision, hemostasis, and coagulation with a relatively high penetration depth into biological tissues (73). Moreover, they save space and cost less than other laser systems.

## **Research review of lasers used for direct pulp capping**

### **Carbon dioxide (CO<sub>2</sub>) lasers**

*In vitro/animal studies:* In 1985, Melcer et al. (74) reported that a CO<sub>2</sub> laser produced newly mineralized dentin formation without cellular modification of the pulpal tissue when tooth cavities were irradiated in beagles and primates. Two years later, these investigators (75)

utilized the CO<sub>2</sub> laser to treat exposed pulp tissues, thus achieving hemostasis in beagles and monkeys/primates. This procedure was performed by exposing the dentin to an energy density of  $2 \times 10^3$  J/cm<sup>2</sup>, after which the first cell layers of the pulp tissue showed rarefaction and cellular degeneration. After three months, neo-formation of approximately 300- $\mu$ m-thick calcified dentin was observed, perhaps due to excitation of the odontoblasts or the production of pulpal cells that had functioned previously. When an energy density of  $10^3$  J/cm<sup>2</sup> was applied to the pulp, partial necrosis led, within a month, to various inflammatory aspects and to a *quasi*-constant regeneration by formation of a 200- $\mu$ m-thick neo-dentin bridge. Less favorable results were reported by Suzuki et al. (76) in a study examining direct pulp capping in rats, which showed that CO<sub>2</sub> laser irradiation (0.5 W at 3 s) was effective for field control. However, the CO<sub>2</sub> laser group showed a very irregular fibrous dentin matrix in the vicinity of the denatured and carbonized tissue, and definite reparative dentin was not formed. According to Anic et al., CO<sub>2</sub> laser should generally be used at less than 1 W for <1 s under anesthesia and cooling air during irradiation of dental pulp tissue (77).

*Clinical studies:* Moritz et al. (78) used a CO<sub>2</sub> laser for direct pulp capping in their clinical trial, and compared the results with those achieved with calcium hydroxide. In the experimental group, an energy level of 1 W with 0.1-second exposure time and 1-second pulse intervals was applied until the exposed pulps were completely coagulated. The caps were then dressed with calcium hydroxide (Life: Kerr, Orange, CA, USA). In the control group, the pulps were capped only with calcium hydroxide. Thermal tests were used for vitality assessment, and the laser Doppler technique was used for direct measurement of the pulpal blood flow. The last recall examination at 12 months demonstrated a success rate of 89% in the experimental group, while the control group exhibited a considerably lower success rate of 68%. Thus, the authors reported positive results following laser-assisted pulp capping (78,79).

#### **Nd:YAG lasers**

*Clinical studies:* Using human primary teeth, Odabas et al. (80) compared the clinical, radiographic, and histopathologic effects of Nd:YAG laser (2 W, 20 Hz) pulpotomy with those of formocresol pulpotomy. Although the teeth in the formocresol group exhibited a slightly higher percentage of clinical and radiographic success at 12 months, there were no statistically significant differences between the groups. Santucci (81) examined the efficacy

of laser-assisted direct pulp capping by comparing the survival rates of permanent teeth treated with Nd:YAG laser (1.75 W, 20 pps, 20 s) and Vitrebond (3M, St. Paul, MN, USA) direct pulp caps to those of permanent teeth treated with the traditional calcium hydroxide direct pulp cap, Dycal (LD Caulk, Milford, CT, USA), over intervals of up to 54 months. The cumulative proportion of teeth surviving post-operatively in the Dycal direct pulp cap group was 89.7% at 1 month, decreased to 79.4% at 3 months, 76% at 6 months, and a mere 43.6% at 54 months. In contrast, the laser and Vitrebond direct pulp cap maintained much higher survival percentages of 98.4% after 1 month, 93.8% at 3 months, 90.3% at 6 months, and 90.3% after 54 months. Therefore, the pulpal response after 6 months as well as the survival rate of teeth from 9 to 54 months was significantly higher in the laser and Vitrebond direct pulp cap group. The authors speculated that this success was likely due to the aforementioned advantages of lasers, including formation of homogeneous reparative dentin at a faster rate.

#### **Er:YAG lasers**

*Animal studies:* Hasheminia et al. (82) investigated the effect of Er:YAG laser (200 mJ/pulse, 5 Hz, 15 s) on the pulp capping of mechanically exposed cat canines and found that the 'laser plus MTA' group showed little improvement compared with the MTA-alone and the 'laser plus calcium hydroxide' groups. Jayawardena et al. (83) verified the healing capacity of the pulp by demonstrating formation of dentin bridges after pulpal exposure with the Er:YAG laser (150 mJ/pulse, 10 pulses) in rats. Wigdor et al. (84) noticed reparative dentin formation after 4 days in dog teeth. Keller and Hibst (85) reported that neo-formation of calcified dentin was observed at 6 and 8 weeks after Er:YAG laser irradiation (150-300 mJ/pulse, 50 pulses) in dog tooth pulp. However, based on the authors' collective experiences, this parameter is not recommended for the treatment of human teeth in clinical settings.

*Clinical studies:* Olivi et al. (86) used an Er:YAG laser (25 mJ/pulse, 20 pps, 10 s) and reported more positive results in two groups of patients with decayed permanent teeth: a child group aged between 11 and 18 years (average: 14.5 years), and an adult group aged between 19 and 40 years (average: 27.1 years). A four-year follow-up showed a success rate of 63% in the child group and 50% in the adult group with calcium hydroxide, equal percentages (80%) in both groups with Er,Cr:YSGG laser, and 75% in the child group and 70% in the adult group with the Er:YAG laser. These results demonstrated that laser

technology has been proven effective in improving the prognosis of pulp capping. With regard to dentin formation, Huth et al. (87) conducted Er:YAG laser pulpotomy (180 mJ/pulse, 2 Hz, approximately 32 pulses) in human primary molar teeth, and obtained clinical success rates of 98% and 93% in 12 and 24 months after treatment, respectively.

### **Er,Cr:YSGG lasers**

*Animal studies:* Toomarian used the Er,Cr:YSGG laser (25 mJ/pulse, 0.5 W, 20 Hz) for pulpotomy in the teeth of dogs and observed no clinical, pathological, or radiographic findings (88).

*Clinical studies:* Olivi et al. studied the use of a 2,780-nm Er,Cr:YSGG laser (0.5 W, 20 pps, 10 s) combined with a self-setting base with calcium hydroxide for direct pulp capping in patients and reported a success rate of 80% in four years (86,89). Blanken et al. studied 9 vital human teeth displaying deep carious lesions that were treated with an Er,Cr:YSGG laser (0.25–0.5 W), pulp-capped with a modified glass-ionomer cement (Vitrebond), and permanently restored with Cavex Clearfil APX (Kuraray, Tokyo, Japan). Clinical and radiographic evaluation conducted 3 to 8 months after treatment showed no clinical signs of inflammation, and the vitality tests were positive in eight cases (90).

### **Diode lasers**

*Animal studies:* Yilmaz et al. reported that diode laser irradiation (0.7-W output power) of the pulpal chamber of extracted human primary first molars did not cause injurious temperature increases (91).

*Clinical studies:* Yazdanfar et al. compared the effectiveness of conventional [resin-modified glass-ionomer cement (Vitrebond) light-hardening paste alone] and diode-laser-assisted (808 nm, 5 W, continuous wave for 2 s per 1 mm) methods in direct pulp capping of carious teeth in ten patients from ages 12 to 40 years (92). The one-year success rate in the diode-laser-assisted group (100%) was significantly better than that of the conventional group (60%) in this pilot study.

## **Current clinical procedures for use of lasers in direct pulp capping: treatment steps including advantages and disadvantages of lasers**

According to endodontic textbooks, uses of a laser for direct pulp capping are extremely limited (52). The best current evidence in the literature for the clinical use of

different types of lasers is summarized in Table 2 and Fig. 1, and describes the practical applications along with academic commentary. This will be particularly useful for dental students, post-graduate residents, and practitioners.

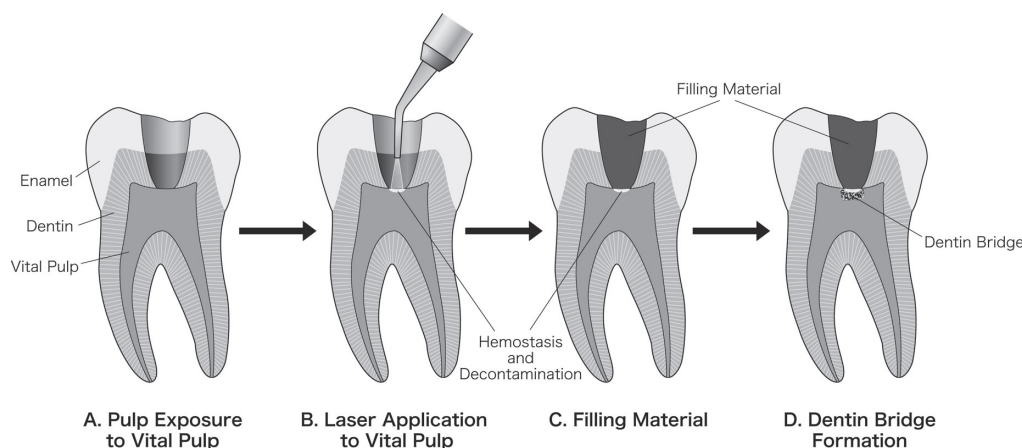
Table 2 summarizes the types of lasers, parameters, indications, advantages, and disadvantages, together with the best current evidence in the literature. The use of lasers for direct pulp capping shows great promise with respect to clinical and basic sciences because of their versatility and wide applicability. However, dental lasers must be studied and practiced sufficiently before they can be routinely applied in the clinic.

Figure 1 is a summary of clinical procedures for direct pulp capping with lasers, based on authors' collective experiences, and illustrates the steps of the treatment. First, careful clinical examination, including a pulp vitality test, is critical to establish a diagnosis. If the diagnosis requires direct pulp capping treatment, local anesthesia is administered to the tooth and a rubber dam is used. The next step is preparation of the dentin surrounding the exposed pulp and complete removal of all softened, carious dentin by means of a high- and low-speed handpiece and/or hand instruments. This must be performed with care to avoid excessive injury to the exposed pulp tissue (Fig. 1A). Depending on the situation, the use of Er:YAG or Er,Cr:YSGG lasers in addition to mechanical treatment may be helpful for hard-tissue preparation as the laser can ablate carious dentin without direct contact (93). Therefore, laser treatment minimizes the mechanical damage to the exposed pulp tissue.

Following preparation of the surrounding dentin, hemostasis and decontamination of the exposed pulp tissue are performed, and the major laser usage occurs at this stage (Fig. 1B). Traditional methods for hemostasis and decontamination include copious irrigation with NaOCl and topical application of Ca(OH)<sub>2</sub> if the hemorrhage is minimal, and topical application of ferric sulfate if the hemorrhage is significant (94). Compressed application of a formocresol-medicated cotton pellet is then performed at the area of hemorrhage. However, the clinical time spent and the treatment outcomes with these traditional methods are uncertain and technique-sensitive (81). In contrast, there are two major advantages (hemostasis and decontamination) to be considered if a laser is used for direct pulp capping procedures. Laser treatment for hemostasis and decontamination is easy to accomplish and less technically demanding as it can achieve the treatment goal without coming into contact with the hemorrhage site, and also sterilize the exposed site and its surrounding area simultaneously. In the non-contact

**Table 2** Lasers used for direct pulp-capping

	Wavelength	Power	Time	Indication	Waveform	Advantages	Disadvantages	References
CO <sub>2</sub>	10,600 nm	0.5 - 1 W Continuous wave and pulsed	0.5 - 3 s	Soft tissue	Continuous and/or gated pulsed mode	Strong hemostasis Decontamination Photobiomodulation Less expensive	Major thermal change (carbonization and strong coagulation) Not able to be guided by optical fibers Large-sized device	Melcer et al. (74) Suzuki et al. (76) Anic et al. (77) Moritz et al. (78, 79)
Nd:YAG	1,064 nm	1.75 - 2 W 20 pps	0.5 - 20 s	Soft tissue	Free-running pulsed mode	Strong hemostasis Decontamination Photobiomodulation Fiber-optic or hollow-wave-guiding delivery	Major thermal change (carbonization and strong coagulation) Expensive and large-sized device	Anic et al. (77) Odabas et al. (80) Santucci (81)
Er:YAG	2,936 nm	25 - 200 mJ/pulse 2 - 20 pps	5 - 15 s	Soft & hard tissue	Free-running pulsed mode	Low to moderate hemostasis Decontamination Photobiomodulation Minimal thermal change (slight coagulation) Fiber-optic delivery	Expensive and large-sized device	Hashemina et al. (82) Jayawardena et al. (83) Wigdor et al. (84) Olivi et al. (86) Huth et al. (87)
Er,Cr:YSGG	2,780 nm	0.25 - 0.5 W (25 mJ/pulse, 10 - 20 pps)	5 - 15 s	Soft & hard tissue	Free-running pulsed mode	Low to moderate hemostasis Decontamination Photobiomodulation Minimal thermal change (slight coagulation) Fiber-optic delivery	Expensive and large-sized device	Olivi et al. (86, 89) Toomarian et al. (88) Blanken et al. (90)
Diode	810-980 nm	0.7 - 5 W Continuous wave	1 - 2 s	Soft tissue	Continuous and/or gated pulsed mode	Strong hemostasis Decontamination Photobiomodulation Wide selections of optical fibers Less expensive and small-sized device Fiber-optic delivery	Major thermal change (carbonization and strong coagulation)	Yilmaz et al. (91) Yazdanfar et al. (92)



**Fig. 1** Treatment steps of direct pulp capping using lasers. **(A)** Exposure of vital pulp. **(B)** Hemostasis and decontamination of the exposed pulp tissue using lasers. **(C)** After laser application and hemostasis establishment, filling material will be applied. **(D)** Dentin bridge formation.

mode, CO<sub>2</sub> laser has the ability to stop blood flow easily during hemostasis as it can seal small blood vessels by thermal coagulation of the soft tissue (95,96). In the case of Nd:YAG laser, dye must be applied to the treated pulp surface except when resin filling is indicated in an ante-

rior tooth (86). The Er:YAG laser lacks sufficient ability to achieve complete hemostasis because its thermal effect is extremely low (86). However, even if hemostasis is not achieved, the conventional procedure following laser treatment controls bleeding more easily after irradiation

compared to cases in which irradiation is not performed (86). The hemostatic effect of diode laser is due to significant absorption of laser light by hemoglobin and melanin, which ensures that the treated area dries within the least possible time. It also provides deeper penetration. The fine area of hemostasis created by this laser includes a thin layer of necrosis, below which there is an area where the injury can be reversed, i.e., a place for migration of inflammatory cells and the fibroblasts that contribute to the formation of the dentinal bridge (86).

In addition to hemostasis, lasers can treat the exposed pulp surface without direct contact. Therefore, the treated wound surface remains sterile, further strengthening the stringent asepsis in combination with dental dam isolation. However, there are some disadvantages of using lasers on an exposed pulp surface. Depending on the kind of laser applied, the pulp tissue and surrounding dentin are damaged thermally due to superficial coagulation/carbonization, causing thick and deep coagulation or necrosis. If inappropriate laser power, time, or technique are used, there is increased risk of excessive ablation or thermal denaturing of the pulp tissue, resulting in inflammation and necrosis (97). A filling material is applied after laser application and establishment of hemostasis (Fig. 1C).

Following a report about wound healing of vital pulp by laser radiation (98), researchers have reported reparative (secondary) dentin formation due to laser radiation (74,75,83,84) (Fig. 1D). Direct pulp capping is the treatment of an exposed vital pulp with a dental material to facilitate formation of a dentin bridge and maintenance of the vital pulp.

### Future directions

From a clinical perspective, all root canal treatments now involve microscopes as part of standard care, but the combination of microscopes and lasers has not been extensively studied. Many clinicians have been clamoring for a microscope that can also harness the power of a laser so as to enable them to cut more accurately (99). Currently, the clinical long-term success rate for laser-assisted pulp capping is approximately 90%, while that for traditional non-laser pulp capping is approximately 60% (78,79,81,83). It is speculated that high-quality, meticulous direct pulp capping involving microscopes and lasers would improve working conditions, increase the effectiveness of the interaction between laser-assisted pulp and capping material, expand case selections/applications, and increase the long-term success rates as compared with the previously reported results (78-81,83,86,100).

From a basic scientific perspective, the current advances in lasers may also contribute to the development of future technologies such as the photo-bio-modulation (PBM) effect as a result of low-level laser irradiation (low-level laser therapy: LLLT) (101). Similar to the successful studies in periodontics (44,102), the PBM effect could also be applied effectively in direct pulp capping and lead to successful reduction of inflammation, stimulation of cells, promotion of cell proliferation, and controlled promotion of partial calcification of the vital pulp. Marques et al. reported low-level laser therapy (LLLT) (660-nm wavelength, 10 mW power output, and 2.5 J/cm<sup>2</sup> energy density for 10 s in continuous mode) as an alternative for pulpotomy in 20 human mandibular primary molar teeth (103). Similarly, Fernandes et al. reported clinical and radiographic evaluations at 6, 12, and 18 post-operative months (104). Based on these studies (103,104), low-level laser therapy preceding the use of calcium hydroxide exhibits satisfactory results for pulp-tissue healing.

The results of clinical studies concerning the various PBM effects have potential, even though they have not yet been clearly demonstrated (105,106). In a study examining the effects of Nd:YAG laser on blood flow in pulp tissue using laser Doppler flowmetry in mandibular canines from 13 human patients, a significant increase of blood flow in the dental pulp was noted in all laser-irradiated (30 s at 120-mJ pulses at 10 pulses/s) teeth (105). Moreover, an *in vitro* study (106) reported that the mineralization of human dental pulp (HDP) cells is stimulated by laser irradiation. Several animal (74,75,85) and clinical (100) studies have reported favorable or potential formation of reparative dentin following laser therapy. Lasers induce calcification, resulting in the formation of ideal reparative dentin to a greater extent than that achieved by traditional methods (83). These benefits of laser treatment may result in greater long-term success of direct pulp capping, making it an advantageous future alternative to the current treatment modality.

### Conflicts of interest

The authors deny any conflicts of interest.

### References

1. Hermann B (1930) Dentinobliteration der wurzelkanäle nach behandlung mit calzium. Zahnärztl Rundschau 39, 888-898.
2. Zander HA (1939) Reaction of the pulp to calcium hydroxide. J Dent Res 18, 373-379.
3. Nyborg H (1955) Healing processes in the pulp on capping; a morphologic study; experiments on surgical lesions of the pulp in dog and man. Acta Odontol Scand 13, Suppl 16,



- 1-130.
4. Cvek M (1978) A clinical report on partial pulpotomy and capping with calcium hydroxide in permanent incisors with complicated crown fracture. *J Endod* 4, 232-237.
  5. Haskell EW, Stanley HR, Chellemi J, Stringfellow H (1978) Direct pulp capping treatment: a long-term follow-up. *J Am Dent Assoc* 97, 607-612.
  6. Baume LJ, Holz J (1981) Long term clinical assessment of direct pulp capping. *Int Dent J* 31, 251-260.
  7. Horsted P, Sandergaard B, Thylstrup A, El Attar K, Fejerskov O (1985) A retrospective study of direct pulp capping with calcium hydroxide compounds. *Endod Dent Traumatol* 1, 29-34.
  8. Schröder U (1985) Effects of calcium hydroxide-containing pulp-capping agents on pulp cell migration, proliferation, and differentiation. *J Dent Res* 64, Spec, 541-548.
  9. Yamamura T (1985) Differentiation of pulpal cells and inductive influences of various matrices with reference to pulpal wound healing. *J Dent Res* 64, Spec, 530-540.
  10. Barthel CR, Rosenkranz B, Leuenberg A, Roulet JF (2000) Pulp capping of carious exposures: treatment outcome after 5 and 10 years: a retrospective study. *J Endod* 26, 525-528.
  11. Al-Hiyasat AS, Barriehi-Nusair KM, Al-Omari MA (2006) The radiographic outcomes of direct pulp-capping procedures performed by dental students: a retrospective study. *J Am Dent Assoc* 137, 1699-1705.
  12. Torabinejad M, Pitt Ford TR (1996) Root end filling materials: a review. *Endod Dent Traumatol* 12, 161-178.
  13. Witherspoon DJ, Robertson HM (2003) Neutral evolution of ten types of mariner transposons in the genomes of *Caenorhabditis elegans* and *Caenorhabditis briggsae*. *J Mol Evol* 56, 751-769.
  14. Aeinehchi M, Eslami B, Ghanbariha M, Saffar AS (2003) Mineral trioxide aggregate (MTA) and calcium hydroxide as pulp-capping agents in human teeth: a preliminary report. *Int Endod J* 36, 225-231.
  15. Menezes R, Bramante CM, Letra A, Carvalho VG, Garcia RB (2004) Histologic evaluation of pulpotomies in dog using two types of mineral trioxide aggregate and regular and white Portland cements as wound dressings. *Oral Surg Oral Med Oral Pathol Oral Radiol Endod* 98, 376-379.
  16. Chacko V, Kurikose S (2006) Human pulpal response to mineral trioxide aggregate (MTA): a histologic study. *J Clin Pediatr Dent* 30, 203-209.
  17. Farsi N, Alamoudi N, Balto K, Al Mushayt A (2006) Clinical assessment of mineral trioxide aggregate (MTA) as direct pulp capping in young permanent teeth. *J Clin Pediatr Dent* 31, 72-76.
  18. Accorinte Mde L, Holland R, Reis A, Bortoluzzi MC, Murata SS, Dezan E Jr et al. (2008) Evaluation of mineral trioxide aggregate and calcium hydroxide cement as pulp-capping agents in human teeth. *J Endod* 34, 1-6.
  19. Bogen G, Kim JS, Bakland LK (2008) Direct pulp capping with mineral trioxide aggregate: an observational study. *J Am Dent Assoc* 139, 305-315.
  20. Nair PN, Duncan HF, Pitt Ford TR, Luder HU (2008) Histological, ultrastructural and quantitative investigations on the response of healthy human pulps to experimental capping with mineral trioxide aggregate: a randomized controlled trial. *Int Endod J* 41, 128-150.
  21. Mente J, Geletneky B, Ohle M, Koch MJ, Friedrich Ding PG, Wolff D et al. (2010) Mineral trioxide aggregate or calcium hydroxide direct pulp capping: an analysis of the clinical treatment outcome. *J Endod* 36, 806-813.
  22. Kitasako Y, Inokoshi S, Tagami J (1999) Effects of direct resin pulp capping techniques on short-term response of mechanically exposed pulps. *J Dent* 27, 257-263.
  23. Hebling J, Giro EM, Costa CA (1999) Human pulp response after an adhesive system application in deep cavities. *J Dent* 27, 557-564.
  24. de Souza Costa CA, Lopes do Nascimento AB, Teixeira HM, Fontana UF (2001) Response of human pulps capped with a self-etching adhesive system. *Dent Mater* 17, 230-240.
  25. Hörsted-Bindslev P, Vilkinis V, Sidlauskas A (2003) Direct capping of human pulps with a dentin bonding system or with calcium hydroxide cement. *Oral Surg Oral Med Oral Pathol Oral Radiol Endod* 96, 591-600.
  26. Kitamura C, Ogawa Y, Morotomi T, Terashita M (2003) Differential induction of apoptosis by capping agents during pulp wound healing. *J Endod* 29, 41-43.
  27. Accorinte Mde L, Loguercio AD, Reis A, Muench A, de Araújo VC (2005) Adverse effects of human pulps after direct pulp capping with the different components from a total-etch, three-step adhesive system. *Dent Mater* 21, 599-607.
  28. Imaizumi N, Kondo H, Ohya K, Kasugai S, Araki K, Kurosaki N (2006) Effects of exposure to 4-META/MMA-TBB resin on pulp cell viability. *J Med Dent Sci* 53, 127-133.
  29. Lin L, Langeland K (1981) Light and electron microscopic study of teeth with carious pulp exposures. *Oral Surg Oral Med Oral Pathol* 51, 292-316.
  30. Langeland K (1981) Management of the inflamed pulp associated with deep carious lesion. *J Endod* 7, 169-181.
  31. Bergenholtz G, Mjör IA, Cotton WR, Hanks CT, Kim S, Torneck CD et al. (1985) The biology of dentin and pulp. Consensus report. *J Dent Res* 64, Spec, 631-633.
  32. Couve E (1986) Ultrastructural changes during the life cycle of human odontoblasts. *Arch Oral Biol* 31, 643-651.
  33. Pashley DH (1996) Dynamics of the pulpo-dentin complex. *Crit Rev Oral Biol Med* 7, 104-133.
  34. Glass RL, Zander HA (1949) Pulp healing. *J Dent Res* 28, 97-107.
  35. Zander HA, Glass RL (1949) The healing of phenolized pulp exposures. *Oral Surg Oral Med Oral Pathol* 2, 803-810.
  36. Bergenholtz G (2005) Advances since the paper by Zander and Glass (1949) on the pursuit of healing methods for pulpal exposures: historical perspectives. *Oral Surg Oral Med Oral Pathol Oral Radiol Endod* 100, S102-108.
  37. Matsuo T, Nakanishi T, Shimizu H, Ebisu S (1996) A clinical study of direct pulp capping applied to carious-exposed pulps. *J Endod* 22, 551-556.

38. Lee MT, Bird PS, Walsh LJ (2004) Photo-activated disinfection of the root canal: a new role for lasers in endodontics. *Aust Endod J* 30, 93-98.
39. Stabholz A, Sahar-Helft S, Moshonov J (2004) Lasers in endodontics. *Dent Clin North Am* 48, 809-832.
40. Parker S (2007) Surgical laser use in implantology and endodontics. *Br Dent J* 202, 377-386.
41. JOE Editorial Board (2008) Lasers in endodontics: an online study guide. *J Endod* 34, e33-36.
42. Mohammadi Z (2009) Laser applications in endodontics: an update review. *Int Dent J* 59, 35-46.
43. Jafarzadeh H (2009) Laser Doppler flowmetry in endodontics: a review. *Int Endod J* 42, 476-490.
44. Aoki A, Sasaki KM, Watanabe H, Ishikawa I (2004) Lasers in nonsurgical periodontal therapy. *Periodontol* 2000 36, 59-97.
45. Sulewski JG (2000) Historical survey of laser dentistry. *Dent Clin North Am* 44, 717-752.
46. Convissar RA (2004) The biologic rationale for the use of lasers in dentistry. *Dent Clin North Am* 48, 771-794.
47. Maiman TH (1960) Stimulated optical radiation in ruby. *Nature* 187, 493-494.
48. Javan A, Bennett WR Jr, Herriott DR (1961) Population inversion and continuous optical maser oscillation in a gas discharge containing a He-Ne mixture. *Physiol Rev Letter* 6, 106-110.
49. Geusic JE, Marcos HM, Van Uitert LG (1964) Laser oscillations in Nd-doped yttrium aluminum, yttrium gallium and gadolinium garnets. *Appl Phys Lett* 4, 182-184.
50. Stern RH, Sognaes RF (1965) Laser effect on dental hard tissues. A preliminary report. *J South Calif Dent Assoc* 33, 17-19.
51. Weichman JA, Johnson FM (1971) Laser use in endodontics. A preliminary investigation. *Oral Surg Oral Med Oral Pathol* 31, 416-420.
52. Matsumoto K (2000) Lasers in endodontics. *Dent Clin North Am* 44, 889-906.
53. Fried D, Glana RE, Featherstone JD, Seka W (1997) Permanent and transient changes in the reflectance of CO<sub>2</sub> laser-irradiated dental hard tissues at  $\lambda = 9.3, 9.6, 10.3,$  and  $10.6 \mu\text{m}$  and at fluences of 1-20 J/cm<sup>2</sup>. *Lasers Surg Med* 20, 22-31.
54. Wigdor HA, Walsh JT Jr (2002) Histologic analysis of the effect on dental pulp of a 9.6- $\mu\text{m}$  CO<sub>2</sub> laser. *Lasers Surg Med* 30, 261-266.
55. Myers TD, Myers WD, Stone RM (1989) First soft tissue study utilizing a pulsed Nd:YAG dental laser. *Northwest Dent* 68, 14-17.
56. Coluzzi DJ (2000) An overview of laser wavelengths used in dentistry. *Dent Clin North Am* 44, 753-765.
57. Pick RM, Colvard MD (1993) Current status of lasers in soft tissue dental surgery. *J Periodontol* 64, 589-602.
58. Shoji S, Hariu H, Horiuchi H (2000) Canal enlargement by Er:YAG laser using a cone-shaped irradiation tip. *J Endod* 26, 454-458.
59. Stabholz A, Zeltser R, Sela M, Peretz B, Moshonov J, Ziskind D et al. (2003) The use of lasers in dentistry: principles of operation and clinical applications. *Compend Contin Educ Dent* 24, 935-948.
60. White JM, Goodis HE, Rose CL (1991) Use of the pulsed Nd:YAG laser for intraoral soft tissue surgery. *Lasers Surg Med* 11, 455-461.
61. Yukna RA, Carr RL, Evans GH (2007) Histologic evaluation of an Nd:YAG laser-assisted new attachment procedure in humans. *Int J Periodontics Restorative Dent* 27, 577-587.
62. Romanos GE, Everts H, Nentwig GH (2000) Effects of diode and Nd:YAG laser irradiation on titanium discs: a scanning electron microscope examination. *J Periodontol* 71, 810-815.
63. Ebihara A, Anjo T, Takeda A, Suda H (2004) The surface of root canal irradiated by Nd:YAG laser with TiO<sub>2</sub>. *Proc SPIE* 5313, 97-103.
64. Hale GM, Querry MR (1973) Optical constants of water in the 200-nm to 200- $\mu\text{m}$  wavelength region. *Appl Opt* 12, 555-563.
65. Hibst R, Keller U (1989) Experimental studies of the application of the Er:YAG laser on dental hard substances: I. Measurement of the ablation rate. *Lasers Surg Med* 9, 338-344.
66. Keller U, Hibst R (1989) Experimental studies of the application of the Er:YAG laser on dental hard substances: II. Light microscopic and SEM investigations. *Lasers Surg Med* 9, 345-351.
67. Sasaki KM, Aoki A, Ichinose S, Ishikawa I (2002) Ultrastructural analysis of bone tissue irradiated by Er:YAG laser. *Lasers Surg Med* 31, 322-332.
68. Lewandrowski KU, Lorente C, Schomacker KT, Flotte TJ, Wilkes JW, Deutsch TF (1996) Use of the Er:YAG laser for improved plating in maxillofacial surgery: comparison of bone healing in laser and drill osteotomies. *Lasers Surg Med* 19, 40-45.
69. Bornstein E (2004) Proper use of Er:YAG lasers and contact sapphire tips when cutting teeth and bone: scientific principles and clinical application. *Dent Today* 23, 84, 86-89.
70. Schwarz F, Olivier W, Herten M, Sager M, Chaker A, Becker J (2007) Influence of implant bed preparation using an Er:YAG laser on the osseointegration of titanium implants: a histomorphometrical study in dogs. *J Oral Rehabil* 34, 273-281.
71. Stübinger S, Nuss K, Landes C, von Rechenberg B, Sader R (2008) Harvesting of intraoral autogenous block grafts from the chin and ramus region: preliminary results with a variable square pulse Er:YAG laser. *Lasers Surg Med* 40, 312-318.
72. Featherstone JD (2000) Caries detection and prevention with laser energy. *Dent Clin North Am* 44, 955-969.
73. Romanos G, Nentwig GH (1999) Diode laser (980 nm) in oral and maxillofacial surgical procedures: clinical observations based on clinical applications. *J Clin Laser Med Surg* 17, 193-197.
74. Melcer J, Chaumette MT, Melcer F, Zeboulon S, Hasson R, Merard R et al. (1985) Preliminary report on the effect of the CO<sub>2</sub> laser beam on the dental pulp of the *Macaca mulatta*

- primate and the beagle dog. *J Endod* 11, 1-5.
75. Melcer J, Chaumette MT, Melcer F (1987) Dental pulp exposed to the CO<sub>2</sub> laser beam. *Lasers Surg Med* 7, 347-352.
  76. Suzuki M, Katsumi A, Watanabe R, Shirono M, Katoh Y (2005) Effects of an experimentally developed adhesive resin system and CO<sub>2</sub> laser irradiation on direct pulp capping. *Oper Dent* 30, 702-718.
  77. Anić I, Tachibana H, Masumoto K, Qi P (1996) Permeability, morphologic and temperature changes of canal dentine walls induced by Nd: YAG, CO<sub>2</sub> and argon lasers. *Int Endod J* 29, 13-22.
  78. Moritz A, Schoop U, Goharkhay K, Sperr W (1998) The CO<sub>2</sub> laser as an aid in direct pulp capping. *J Endod* 24, 248-251.
  79. Moritz A, Schoop U, Goharkhay K, Sperr W (1998) Advantages of a pulsed CO<sub>2</sub> laser in direct pulp capping: a long-term in vivo study. *Lasers Surg Med* 22, 288-293.
  80. Odabaş ME, Bodur H, Barış E, Demir C (2007) Clinical, radiographic, and histopathologic evaluation of Nd:YAG laser pulpotomy on human primary teeth. *J Endod* 33, 415-421.
  81. Santucci PJ (1999) Dycal versus Nd:YAG laser and Vitrebond for direct pulp capping in permanent teeth. *J Clin Laser Med Surg* 17, 69-75.
  82. Hasheminia SM, Feizi G, Razavi SM, Feizianfard M, Gutknecht N, Mir M (2010) A comparative study of three treatment methods of direct pulp capping in canine teeth of cats: a histologic evaluation. *Lasers Med Sci* 25, 9-15.
  83. Jayawardena JA, Kato J, Moriya K, Takagi Y (2001) Pulpal response to exposure with Er:YAG laser. *Oral Surg Oral Med Oral Pathol Oral Radiol Endod* 91, 222-229.
  84. Wigdor H, Abt E, Ashrafi S, Walsh JT Jr (1993) The effect of lasers on dental hard tissues. *J Am Dent Assoc* 124, 65-70.
  85. Keller U, Hibst R (1991) Tooth pulp reaction following Er:YAG laser application. *Proc SPIE* 1424, 127-133.
  86. Olivi G, Genovese MD, Maturo P, Docimo R (2007) Pulp capping: advantages of using laser technology. *Eur J Paediatr Dent* 8, 89-95.
  87. Huth KC, Paschos E, Hajek-Al-Khatat N, Hollweck R, Crispin A, Hickel R et al. (2005) Effectiveness of 4 pulpotomy techniques--randomized controlled trial. *J Dent Res* 84, 1144-1148.
  88. Toomarian L, Fekrazad R, Sharifi D, Baghaei M, Rahimi H, Eslami B (2008) Histopathological evaluation of pulpotomy with Er,Cr:YSGG laser vs formocresol. *Lasers Med Sci* 23, 443-450.
  89. Olivi G, Genovese M (2006) Erbium chromium laser in pulp capping treatment. *J Oral Laser Applic* 6, 291-299.
  90. Blanken JW (2005) Direct pulp capping using an Er,Cr:YSGG laser. *J Oral Laser Applic* 5, 107-114.
  91. Yilmaz Y, Keles S, Mete A (2013) Temperature changes in the pulpal chamber and the sealing performance of various methods of direct pulp capping of primary teeth. *Eur J Paediatr Dent* 14, 95-100.
  92. Yazdanfar I, Gutknecht N, Franzen R (2015) Effects of diode laser on direct pulp capping treatment: a pilot study. *Lasers Med Sci* 30, 1237-1243.
  93. van As G (2004) Erbium lasers in dentistry. *Dent Clin North Am* 48, 1017-1059.
  94. Jeansonne BG, Boggs WS, Lemon RR (1993) Ferric sulfate hemostasis: effect on osseous wound healing. II. With curettage and irrigation. *J Endod* 19, 174-176.
  95. Sutton C (1995) Power sources in endoscopic surgery. *Curr Opin Obstet Gynecol* 7, 248-256.
  96. Kravitz ND, Kusnoto B (2008) Soft-tissue lasers in orthodontics: an overview. *Am J Orthod Dentofacial Orthop* 133, S110-114.
  97. White JM, Frewin CR, Kaur M, Flavel S, McGregor C (1994) Twenty-four hour ambulatory monitoring of tremor, sweating, skin temperature and locomotor activity in the alcohol withdrawal syndrome. *Clin Auton Res* 4, 15-18.
  98. Mester E, Spiry T, Szende B, Tota JG (1971) Effect of laser rays on wound healing. *Am J Surg* 122, 532-535.
  99. Saegusa H, Watanabe S, Anjo T, Ebihara A, Suda H (2010) Safety of laser use under the dental microscope. *Aust Endod J* 36, 6-11.
  100. Nair PN, Baltensperger M, Luder HU, Eyrich GK (2005) Observations on pulpal response to carbon dioxide laser drilling of dentine in healthy human third molars. *Lasers Med Sci* 19, 240-247.
  101. Ohshiro T, Calderhead RG (1991) Development of low reactive-level laser therapy and its present status. *J Clin Laser Med Surg* 9, 267-275.
  102. Izumi Y, Aoki A, Yamada Y, Kobayashi H, Iwata T, Akizuki T et al. (2011) Current and future periodontal tissue engineering. *Periodontol* 2000 56, 166-187.
  103. Marques NC, Neto NL, Rodini CD, Fernandes AP, Sakai VT, Machado MA et al. (2014) Low-level laser therapy as an alternative for pulpotomy in human primary teeth. *Lasers Med Sci* doi: 10.1007/s10103-014-1656-7.
  104. Fernandes AP, Lourenço Neto N, Teixeira Marques NC, Silveira Moretti AB, Sakai VT, Cruvinel Silva T et al. (2015) Clinical and radiographic outcomes of the use of low-level laser therapy in vital pulp of primary teeth. *Int J Paediatr Dent* 25, 144-150.
  105. Yamaguchi H, Kobayashi K, Sato Y, Osada R, Sakuraba E, Nomura T et al. (2000) Nd:YAG laser irradiation of the human dental pulp: implications as a predictor of pulp hemodynamics. *Lasers Surg Med* 26, 270-276.
  106. Matsui S, Tsujimoto Y, Matsushima K (2007) Stimulatory effects of hydroxyl radical generation by Ga-Al-As laser irradiation on mineralization ability of human dental pulp cells. *Biol Pharm Bull* 30, 27-31.

Copyright of Journal of Oral Science is the property of Nihon University School of Dentistry and its content may not be copied or emailed to multiple sites or posted to a listserv without the copyright holder's express written permission. However, users may print, download, or email articles for individual use.