

12-1-2017

The Effect Of A Stability And Strengthening Program On The Oswestry Disability Index In A 14-Year-Old Patient With Spondylolisthesis: A Case Report

Hormoz Maragoul
University of New England

Follow this and additional works at: http://dune.une.edu/pt_studcrpaper

 Part of the [Physical Therapy Commons](#)

© 2017 Hormoz Maragoul

Recommended Citation

Maragoul, Hormoz, "The Effect Of A Stability And Strengthening Program On The Oswestry Disability Index In A 14-Year-Old Patient With Spondylolisthesis: A Case Report" (2017). *Case Report Papers*. 80.
http://dune.une.edu/pt_studcrpaper/80

This Course Paper is brought to you for free and open access by the Physical Therapy Student Papers at DUNE: DigitalUNE. It has been accepted for inclusion in Case Report Papers by an authorized administrator of DUNE: DigitalUNE. For more information, please contact bkenyon@une.edu.

Maragoul, *The Effect of a Stability and Strengthening Program on the Oswestry Disability Index in a 14-year-old Patient with Spondylolisthesis: A Case Report.*

1
2
3
4
5
6
7
8
9
10
11
12
13
14
15
16
17
18
19
20
21
22
23
24

University of New England

Department of Physical Therapy

PTH 608/708: Case Report Template

Name: Hormoz Maragoul - Title: Maragoul, The Effect of a Stability and Strengthening Program on the Oswestry Disability Index in a 14-year-old Patient with Spondylolisthesis: A Case Report.

Please use this template for Week 2-12 assignments, as clearly outlined both in blackboard and the syllabus, by entering the necessary information into each section under the appropriate headers as assigned and submitting to blackboard. Once a section is complete and has been graded, you may delete the instructions provided in grey. Feel free to work ahead as your case allows, but only assigned sections will be graded by the due dates. Please start by adding your name above and in the header, and once you develop your title, a “running” or abbreviated title. This same template will be used for PTH708, and will be completed throughout the fall.

All responses should be in black text, 12-font, Times New Roman, and double-spaced with proper grammar and punctuation. Track changes must be switched OFF. Any assignments submitted in unacceptable condition as determined by the faculty will be returned to the student for resubmission in three days for a maximum score of 80%.

All case reports are written in *past tense*, so ensure that your submissions are past tense. No patient initials are necessary; please refer to your subject as “patient” throughout the manuscript.

25
26
27
28
29
30
31
32
33
34
35
36
37
38
39
40
41
42
43
44
45
46
47
48

Academic Honesty:

You may use any resources at your disposal to complete the assignment. You may not communicate with other UNE students to obtain answers to assignments or share sources to submit. Proper citations must be used for referencing others' published work. If you have questions, please contact a PTH608 course instructor. Any violation of these conditions will be considered academic dishonesty.

By entering your name, you are affirming that you will complete ALL the assignments as original work. Completing an assignment for someone else is unethical and is a form of academic dishonesty.

Student Name: Hormoz Maragoul Date: 6/24/17

By typing your name here, it is representative of your signature.

49
50
51
52
53
54
55
56
57
58
59
60
61
62
63
64
65
66
67
68
69
70
71
72
73
74
75

The Effect of a Stability and Strengthening Program on the Oswestry Disability Index in a 14-year-old Patient with Spondylolisthesis: A Case Report.

Hormoz Maragoul, SPT

Hormoz Maragoul is a student at the
University of New England, 716 Stevens Ave. Portland ME 04103

All communication must be addressed to Hormoz Maragoul

At hmaragoul@une.edu

The patient signed an informed consent allowing the use of medical information for this report and was informed of the policies regarding the Health Insurance Portability and Accountability

Act

The author acknowledges Michael Fillyaw for assistance with case report organization as well as
Laura Roach for assistance with the patient’s care during the clinical practicum

76 **Abstract**

77 **Background and Purpose.** Spondylolisthesis is a condition that describes the anterior
78 translation of the cephalad vertebral segment of the skeletal spine relative to the caudal segment.
79 This condition comes about by forces of gravity acting through the lordotic curve of the lumbar
80 spine. Repetitive extension movements and weakened stabilizing muscles of the trunk like the
81 abdominals and the gluteals may also play a role in contributing to spondylolisthesis. There is an
82 increase in incidence rate of spondylolisthesis in adolescents who participate in sports involving
83 repetitive extension motions. The purpose of this study is to examine the effectiveness of
84 physical therapy management aimed at stability and strengthening for an adolescent with
85 spondylolisthesis.

86 **Case Description.** The patient was a 14-year-old female who was referred to an outpatient
87 orthopedic physical therapy clinic diagnosed with spondylolisthesis at the level of L5 with
88 imaging. Upon evaluation, the patient demonstrated hyperflexibility, joint hypomobility,
89 weakness and instability. Treatments included gluteals and abdominal strengthening and
90 stabilization. The Oswestry Disability Index (ODI) was used to quantify impairment and to
91 measure improvement over the episode of care.

92 **Outcomes.** During the initial evaluation, the patient reported a Numeric Pain Rating Scale
93 (NPRS) of 6/10 at worse, an ODI score of 62% and a Manual Muscle Testing (MMT) grade of
94 2/5, 3/5 and 3/5 for transverse abdominus, hip extension and hip abduction, respectively. At the
95 four-week point the patient reported a NPRS of 4/10 at worse, an ODI score of 20% and a MMT
96 of 2+/5 for transverse abdominus with no change for hip extension and hip abduction. Results
97 improved further during discharge with a reported 2/10 on the NPRS, a 7% on the ODI and
98 MMT improvements to 3/5, 4/5 and 4/5 for transverse abdominus, hip extension and hip
99 abduction, respectively.

100
101
102
103
104
105
106
107
108
109
110
111
112
113
114
115
116
117
118
119
120
121
122
123
124
125
126
127
128
129
130
131
132
133
134
135
136
137
138
139
140
141
142

Discussion. Abdominal stabilization and gluteal strengthening seem to have a positive effect in reducing both pain and ODI score of a fourteen-year-old dancer with low back pain caused by spondylolisthesis.

3053 Words

143
144
145

Background and Purpose

146 Spondylolisthesis is a condition that describes the anterior translation of the cephalad
147 vertebral segment of the skeletal spine relative to the caudal segment. This condition comes
148 about by forces of gravity acting through the lordotic curve of the lumbar spine. These forces
149 may also consist of contractions of the posteriorly located erector spinae or the anteriorly located
150 psoas muscle group. Repetitive extension movements and weakened stabilizing muscles of the
151 trunk like the abdominals and the gluteals may also play a role in contributing to
152 spondylolisthesis. The lumbosacral segment is the most commonly affected with symptoms
153 possibly appearing as pain that is radicular or central.¹

154 Developing spondylolisthesis is rare after the end of spinal growth and into adulthood.²
155 At the age of eighteen, there is a six to seven percent incidence rate for development of
156 spondylolisthesis and during adolescence, those who participate in active sports involving
157 repetitive extension activities such as dance and gymnastics have an increased incidence rate.²

158 Classification of spondylolisthesis is important for measuring improvements made by the
159 patient as well as a guideline for precautions and progressions. Meyerding's grading system uses
160 five grades to describe the percent of anterior slippage: Grade I is 0-25%, grade II is 25-50%,
161 grade III is 50-75%, grade IV is 75-100% and grade VI is greater than 100%.³ Treatment
162 effectiveness is measured both radiographically and symptomatically. The Oswestry Disability
163 Index (ODI) is a reliable tool for determining the improvement during or after a plan of care and
164 is often used to determine the severity of low back pain on effect on function.^{4,5}

165 Treatment for spondylolisthesis is dependent on the patient's age, years of remaining
166 growth, severity and degree of vertebral displacement. Conservative treatment usually involves
167 rest and physical therapy, while surgical treatment involves direct repair of the displaced

168 vertebrae. Physical therapy interventions are aimed at reducing extension stresses in the lumbar
169 spine by relieving tightness of the hip flexors and erector spinae and strengthening the abdominal
170 muscles.² Stabilization exercises are often selected as the intervention of choice for patients who
171 present with instability. Hicks et al⁶ looked at many aspects such as strength and mobility and
172 concluded that four variables were indicative of success with stabilization exercises: positive
173 prone segmental instability test, aberrant movements, average straight leg raise (SLR) greater
174 than 91 degrees, and age less than 40 years old. The study stated that having three or more of
175 these signs is a good indicator of success with stabilization exercises with patients who present
176 with low back pain.⁶ The purpose of this case study is to assess the effectiveness of a stability
177 and strengthening program in an adolescent patient with low back pain secondary to
178 spondylolisthesis as measured by the ODI.

179

180 **Patient History and Systems Review**

181 The patient was a 14-year-old female who presented to an outpatient orthopedic clinic
182 with a referral from an orthopedist and primary care physician with a diagnosis of low back pain
183 secondary to spondylolisthesis. The patient had received a prior episode of physical therapy for
184 her current condition but was discontinued due to a rest recommendation by her orthopedist.
185 Upon evaluation, the patient presented with signs and symptoms consistent with
186 spondylolisthesis and her primary complaints were low back pain localized in the lumbar spine
187 with occasional radiating symptoms in bilateral gluteals and upper quadriceps. The patient
188 reported varying levels of pain intensity that exacerbated with lumbar extension motions and
189 ameliorated with rest. X-ray and magnetic resonance imaging (MRI) taken two-months prior to
190 attending physical therapy confirmed a stress fracture of the pars interarticularis of L5 segment.
191 Past medical history as cited from her medical chart provided by her pediatrician included

192 constipation, anger behavioral concern, knee strain, slipped patella, seizures during infancy,
193 bilateral bunions and moderate intermittent asthma. The doctor indicated that the mechanism of
194 injury likely included repetitive extension motions during dance and jazz programs.
195 Comorbidities included asthma, depression, allergies, headaches and epilepsy. Since the patient
196 was a minor, consent for the case study was requested and granted by both parent and patient.
197 Patient and guardian agreed that the goal for physical therapy was to return to dance.

198 The patient's self-rating of overall health was good and both her mother and herself
199 reported an excellent quality of life. The patient's cardiopulmonary and integumentary systems
200 were unremarkable with communication and cognition unimpaired. The patient's neuromuscular
201 system was deemed impaired due to the initial reports of radiating symptoms from the patient,
202 even as no signs were present during evaluation. The patient also presented with hip weakness,
203 anterior pelvic tilt, forward head and rounded shoulders posture. Table 1 summarizes the results
204 of the systems review.

205

206 **Clinical Impression 1**

207 The patient was referred to physical therapy with a medical diagnosis of spondylolisthesis
208 which was confirmed through imaging. Upon evaluation, she presented with low back pain and
209 signs and symptoms consistent with the referring diagnosis. However, to be considered are
210 juvenile arthritic changes, disc pathology, muscular pathology, neural tension, or sacroiliac
211 pathology. The goal for the initial evaluation was aimed at confirming spondylolisthesis and
212 ruling out differential diagnoses. The tests and measures used during the initial evaluation
213 included manual muscle testing (MMT) for abduction, extension and transverse abdominus,
214 posterior to anterior (P-A) mobilizations of lumbar segments centrally and unilaterally,
215 observation, palpation, active lumbar range of motion, and sacroiliac special tests. Because

216 imaging and clinical tests and measures have demonstrated consistency, spondylolisthesis may
217 be considered a likely diagnosis. With the high incidence rate of spondylolisthesis in adolescent
218 athletes,² this patient was a good subject for a case report for because stability and strength in
219 young patients is an important consideration for the longevity of their participation in physical
220 activity as they transition into adulthood.

221

222 **Examination – Tests and Measures**

223 The patient completed an ODI and a numeric pain rating scale (NPRS) for pain severity.
224 The ODI is a subjective outcome measure used to determine the effect of low back pain on the
225 ability to perform functional activities with a sensitivity of 88% and a specificity of 85% .⁴ The
226 NPRS quantifies the severity of pain on a scale of one to ten. The patient reported the best and
227 the worst pain levels experienced during everyday activities. MMT is a form of measurement
228 that generates a quantitative value from a qualitative test of strength of individual muscles⁷ and
229 was used to identify specific muscles of weakness. The gluteus medius, gluteus maximus and
230 transverse abdominus were specifically chosen as the primary area of focus due to their
231 importance in lumbar stabilization. Joint mobility assessment was used to gain a better insight on
232 the increased amount of range of motion noted during active range of motion observation. Joint
233 mobility assessment measured the motion within a joint based on the direction of desired
234 movement. This patient demonstrated hypermobility into extension and rotation. Standardized
235 tests and measures were used during the initial evaluation and have been summarized in Table 2.
236 Many of the tests and measures do not have strong psychometric properties to support use but
237 have been used regularly in the physical therapy field in order to gain an objective understanding
238 of the patient’s impairments.

239

240

241 **Clinical Impression 2**

242 Based on imaging, clinical tests, mechanism of injury and patient report, the patient
243 presentation was consistent with the diagnosis of spondylolisthesis. Joint hypermobility,
244 instability, hip and abdominal weakness, and mechanism of injury all confirm the initial clinical
245 impression. The patient remained a good candidate for this case report due to the strong evidence
246 in favor of the diagnosis and the importance of correction and maintenance of spondylolisthesis
247 in the young active population. The physical therapy diagnosis was low back pain and the
248 medical diagnosis was spondylolisthesis with an ICD-10 code of M54.5.⁸

249 A good prognosis was expected with a reduction in pain symptoms and reported
250 improvement with impairments. This patient's adherence to her orthopedist's recommendation to
251 avoid dance, jazz or gymnastics to prevent lumbar extension motions also contributed to her
252 good prognosis. Since spondylolisthesis is a fracture of the pars interarticularis, time was
253 required to achieve bone healing^{9,10} Adherence to the stabilization program was equally
254 important for improving recovery time, maintaining improvement and preventing sequelae.⁶ The
255 patient required education to understand the importance of adherence to her home exercise
256 program. Review of her physician's notes were considered in directing the plan of care and avoid
257 adverse effects. As the patient progressed through the plan of care, a re-evaluation of strength
258 and control were performed to assess the effectiveness of the program from reported symptoms.
259 Follow up imaging by the physician was performed to insure fracture healing. MMT of the
260 glutes and transverse abdominus control were done after four visits and upon discharge. ODI
261 assessment was re-administered during discharge to evaluate the effectiveness of the treatment
262 on subjective and objective measures and compared with imaging results.

263 The focus of the plan of care was stabilization of the lumbar spine by strengthening weak

264 musculature that is responsible for supporting the low back and activating muscles that may have
265 been underutilized. The focus of strengthening was on the gluteus medias and maximus. The
266 focus of muscle activation was transverse abdominus control and functional movement
267 correction. Patient goals are highlighted in Table 3.

268

269 **Interventions**

270 The patient was seen in the outpatient physical therapy clinic twice a week for an initial two-
271 week period with two follow-up visits a month later. Each session lasted forty-five minutes and
272 began with a ten-minute warm-up on a recumbent bicycle. Coordination of interventions with
273 other personnel during clinic visits was not required as the patient was treated by the same
274 physical therapy student from initial evaluation to discharge. Progressions were made to
275 interventions after patient performance indicated good form and control with proper technique.
276 Instructions were provided to the patient and her mother and the mother recorded the exercises
277 with a cell phone for visual reference when performing the home program.

278 Detailed descriptions of all interventions are provided in Figure 1 and detailed description of
279 intervention progression is provided in Table 6. Proper form for interventions is provided in
280 Figure 1 with the common erroneous form. Interventions were selected to address joint
281 instability and muscle weakness. Exercises were introduced as neuromuscular reeducation and
282 were progressed to strengthening only after the patient gained control and activation. The
283 American College of Sports Medicine reports that improvements in function before eight weeks
284 are due to neuromuscular reeducation rather than strength improvement.¹¹ The patient
285 demonstrated difficulty with aberrant movements during simple isolated isokinetic hip exercises
286 like side lying hip abduction, prone over table hip extension and side lying clams. Biely et al
287 found that aberrant movements, or patterns that deviate from the typical or expected movement

288 pattern, are associated with low back dysfunction.¹¹ Abdominal stabilization exercises included
289 transverse abdominal drawing exercises and balance exercises. Kim et al found that drawing-in
290 maneuver is the best abdominal contraction technique for maximizing transverse abdominus
291 activation and minimize oblique musculature contraction.¹² Abdominal drawing exercises
292 included isometric holds which were progressed to isometric holds with upper and lower
293 extremity movements. Balance exercises included single leg stance with trampoline toss and was
294 progressed to single leg stance on an Airex® brand foam pad. Strengthening exercises included
295 both progressing the isokinetic hip exercises with ankle weights and adding exercises such as
296 squats, side steps and monster walks with Theraband® brand latex bands. When used in
297 conjunction with lumbar stabilization exercises, hip strengthening exercises have been shown to
298 improve objective findings in patients with low back pain.¹³ During the first week, the patient
299 reported soreness that lasted 24 hours after the treatment.

300 During the third week of treatment, the patient demonstrated improvements in muscle
301 activation with decreased aberrant movements during hip exercises. The patient also reported a
302 decrease in muscle soreness at that time. Once muscle control was adequately established, the
303 patient was progressed into strengthening parameters; this included the use of a red Theraband®
304 instead of a yellow for side steps and monster walks.¹⁴ The purpose of the prescribed
305 interventions was to increase the stability in the lumbar spine.¹⁵ All hip strengthening exercises
306 like side lying hip abduction, prone over table hip extension, side lying clams, side steps and
307 backward monster walks with Theraband® and squats with Theraband® were performed to
308 address the weakness in the gluteus medias and maximus found during the performed tests and
309 measures. All transverse abdominus exercises were prescribed to improve neuromuscular control
310 of the transverse abdominus¹⁶ and was progressed to include movements the patient would make
311 during dance routines. It is well documented that task specific activities provide the most benefit

312 for movements within an activity.^{13,17} All interventions for strengthening were progressed when
313 patient was able to perform more than ten repetitions per set with correct control and form as
314 deemed by the physical therapy student.¹⁴ All endurance exercises like side steps were
315 progressed when forty feet no longer produced soreness the next day or forty feet no longer
316 caused fatigue. These criteria were reached based upon patient report.

317 The patient required education on the importance of her home exercise program early on in
318 the plan of care but became adherent to the program shortly after. The patient missed three
319 treatment sessions during the plan of care due to illness but all missed sessions were rescheduled
320 and completed.

321

322 **OUTCOME**

323 Throughout the plan of care, the patient subjectively reported less difficulty performing
324 exercises and a reduction in delayed onset muscle soreness. The patient's ODI score improved
325 from a 62 percent during the initial evaluation to a twenty percent and seven percent at the four-
326 week mark and discharge, respectively. Improvements in the severity of disability were apparent
327 after just four weeks with continued improvement seen at discharge. This placed her in the mild
328 to no disability category of the ODI. The patient's NPRS score also improved from a 6/10 to a
329 2/10 during discharge. MMT scores of transverse abdominus, hip extension and hip abduction
330 improved to 3/5, 4/5 and 4/5, respectively. ROM, joint play assessment and resting posture
331 showed no difference at discharge. Outcomes for the initial evaluation, the four week point and
332 discharge are highlighted in Table 2.

333

334

335

336 **DISCUSSION**

337 Spondylolisthesis is a cause of back pain that may be linked to repetitive extension forces
338 and muscular weakness associated with joint instability.¹ The purpose of this study was to assess
339 the effectiveness of muscular strengthening and stabilization on the pain levels of a 14-year-old
340 dancer. Based on tests and outcome measures, the patient seemed to benefit from a plan of care
341 which included a structured strengthening program of the muscles believed to be important for
342 lower back stabilization. Upon admission, the patient reported increased pain both at rest and
343 during certain tasks. The findings of weakness, instability and excessive ROM deemed it
344 appropriate to develop a plan to target stabilization with a progression from static to dynamic
345 exercises.

346 After four weeks of treatment, the patient demonstrated significant improvement in
347 MMT, NPRS score and ODI. When reevaluated during discharge, the improvements continued
348 with the patient's pain almost becoming negligible allowing her to perform tasks with little
349 difficulty. MMT improvements at the four-week mark may have been attributed to
350 neuromuscular reeducation due to the patient becoming accustomed to the new movement
351 pattern. However, during discharge, it was apparent that any MMT improvements were due to
352 strength gain because of the linear progression in MMT and the need for increased resistance and
353 difficulty of exercises.

354 Since it was hypothesized that the lack of ability to stabilize the lumbar spine while
355 moving into lumbar extension was the cause of continued pain after the initial injury, the
356 reduction in pain after strength gains demonstrated the importance of stabilization in young
357 athletes. These findings are also consistent with Jeong et al,¹³ who highlighted the importance of
358 a stabilization and strengthening program of the gluteals and transverse abdominus to treat for
359 lower back pain. Even though there is a general consensus to the treatment of low back pain

360 associated with spondylolisthesis, the importance of tailoring a plan of care for a young
361 individual who participates in athletic activities, which may contribute to chronic problems, is
362 evident. Further research is necessary to validate the effectiveness of stabilization and
363 strengthening on the active youth population in both genders who participate in a variety of
364 sports and exercise related activities. It may also be important to note the emotions and
365 personalities of this patient population due to the possible skewed subjective reporting, this may
366 be relevant for future research and clinical practice.

367

368

369

370

371

372

373

374

375

376

377

378

379

380

381

382

383

384

385 **REFERENCES**

- 386 1. Tsirikos AI, Garrido EG. Spondylolysis and spondylolisthesis in children and
387 adolescents. [https://www-clinicalkey-com.une.idm.oclc.org/#!/content/medline/2-](https://www-clinicalkey-com.une.idm.oclc.org/#!/content/medline/2-s2.0-20513868)
388 [s2.0-20513868](https://www-clinicalkey-com.une.idm.oclc.org/#!/content/medline/2-s2.0-20513868) *J Bone Joint Surg Br* - June 1, 2010; 92 (6); 751-9
- 389 2. Rossi F1, Dragoni S. Lumbar spondylolysis: occurrence in competitive athletes.
390 Updated achievements in a series of 390 cases. *J Sports Med Phys Fitness*. 1990
391 Dec;30(4):450-2.
- 392 3. Meyerding HW. Low backache and sciatic pain associated with spondylolisthesis and
393 protruded intervertebral disc: incidence, significance, and treatment. *J Bone Joint*
394 *Surg Am*. 1941;23:461–70
- 395 4. Roussel NA, Truijen S, Kerf ID, Lambeets D, Nijs J, Stassijns G. Reliability of the
396 assessment of lumbar range of motion and maximal isometric strength in patients
397 with chronic low back pain. *Arch of Phys Med and Rehabil*. 2008;89(4):788-791.
398 doi:10.1016/j.apmr.2007.09.039.
- 399 5. Rehab Measures - Oswestry Disability Index. The Rehabilitation Measures Database.
400 <http://www.rehabmeasures.org/Lists/RehabMeasures/DispForm.aspx?ID=1114>.
401 Accessed July 27, 2017.
- 402 6. Hicks GE, Fritz JM, Delitto A, McGill SM. Preliminary development of a clinical
403 prediction rule for determining which patients with low back pain will respond to a
404 stabilization exercise program. *Arch of Phys Med and Rehabil*. 2005;86(9):1753-
405 1762. doi: 10.1016/j.apmr.2005.03.033.

- 406 7. Wong CK, Johnson EK. A narrative review of evidence-based recommendations for
407 the physical examination of the lumbar spine, sacroiliac and hip joint
408 complex. *Musculoskeletal Care*. 2012;10(3):149-161. doi:10.1002/msc.1012.
- 409 8. 2017 ICD-10-CM Codes. ICD10Data.com.
410 <http://www.icd10data.com/ICD10CM/Codes>. Accessed July 4, 2017.
- 411 9. Marsell R, Einhorn TA. The Biology of Fracture Healing. *J Injury*. 2011;42(6):551-
412 555. doi:10.1016/j.injury.2011.03.031.
- 413 10. Syrmou E, Tsitsopoulos PP, Marinopoulos D, Tsonidis C, Anagnostopoulos I,
414 Tsitsopoulos PD. Spondylolysis: A review and reappraisal. *Hippokratia*.
415 2010;14(1):17-21.
- 416 11. Biely SA, Silfies SP, Smith SS, Hicks GE. clinical observation of standing trunk
417 movements: what do the aberrant movement patterns tell us? *J Orthop Sports Phys*
418 *Ther*. 2014;44(4):262-272. doi:10.2519/jospt.2014.4988.
- 419 12. Kim B-J, Lee S-K. Effects of three spinal stabilization techniques on activation and
420 thickness of abdominal muscle. *J of Exerc Rehabil*. 2017;13(2):206-209.
421 doi:10.12965/jer.1734900.450.
- 422 13. Jeong U-C, Sim J-H, Kim C-Y, Hwang-Bo G, Nam C-W. The effects of gluteus
423 muscle strengthening exercise and lumbar stabilization exercise on lumbar muscle
424 strength and balance in chronic low back pain patients. *J Phys Ther Sci*.
425 2015;27(12):3813-3816. doi:10.1589/jpts.27.3813.
- 426 14. Ratamess N A, Alvar B A, Evetoch T K, Housh T J, Kibler W B, Kraemer, W J,
427 Triplett N T. American college of sports medicine's progression models in resistance
428 training for healthy adults. *Med Sci Sports Exerc*. 2009;41(3):687-708.
429 doi:10.1249/mss.0b013e3181915670.

- 430 15. Kendall KD, Emery CA, Wiley JP, Ferber R. The effect of the addition of hip
431 strengthening exercises to a lumbopelvic exercise program for the treatment of non-
432 specific low back pain: A randomized controlled trial. *J Sci Med Sport.*
433 2015;18(6):626-631. doi:10.1016/j.jsams.2014.11.006
- 434 16. Evaluation of specific stabilizing exercises in the treatment of chronic low back pain
435 with radiologic diagnosis of spondylolysis or spondylolisthesis. *Manual Therapy.*
436 1998;3(3):164. doi:10.1016/s1356-689x(98)80009
- 437 17. Buckthorpe M, Erskine RM, Fletcher G, Folland JP. Task-specific neural adaptations
438 to isoinertial resistance training. *Scand J Med Sci Sports.* 2014;25(5):640-649.
439 doi:10.1111/sms.12292.
- 440 18. Laslett M, Aprill CN, McDonald B. Provocation sacroiliac joint tests have validity in
441 the diagnosis of sacroiliac joint pain. *Arch of Phys Med and Rehabil.* 2006;87(6):874.
442 doi:10.1016/j.apmr.2006.04.007.
- 443 19. Frost H, Lamb SE, Stewart-Brown S. Responsiveness of a patient specific outcome
444 measure compared with the oswestry disability index v2.1 and roland and morris
445 disability questionnaire for patients with subacute and chronic low back pain. *Spine.*
446 2008;33(22):2450-2457. doi:10.1097/brs.0b013e31818916fd.
- 447 20. Kendall FP, McCreary EK, Provance PG. Muscles: Testing and Function with
448 Posture and Pain, ed 5. *Phys Ther.* January 2006. doi:10.1093/ptj/86.2.304.
- 449 21. Kaltenborn F, Vallowitz E. Manual Mobilization of the Joint – Vol. 1: The
450 Extremities ed 8. *Orthopedic Physical Therapy Products.* December 2014.
- 451 22. Kaltenborn F, Vallowitz E. Manual Mobilization of the Joint – Vol. 2: The Spine ed
452 6. *Norli.* December 2012.

- 453 23. O’Sullivan SB, Schmitz TJ, Fulk GD. *Physical Rehabilitation*, ed 6. *FA Davis*. July
454 2013.
- 455 24. Hoppenfeld S. *Physical Examination of the Spine and Extremities. Prentice Hall.*
456 June 1976.
- 457 25. Saeterbakken AH, Andersen V, Behm DG, Krohn-Hansen EK, Smaamo M, Fimland
458 MS. Resistance-training exercises with different stability requirements: time course of
459 task specificity. *Eur J Appl Physiol.* 2016;116(11-12):2247-2256.
460 doi:10.1007/s00421-016-3470-3.
- 461 26. Teyhen DS, Flynn TW, Childs JD, Abraham LD. Arthrokinematics in a subgroup of
462 patients likely to benefit from a lumbar stabilization exercise program. *Phys Ther.*
463 2007;87(3):313-325. doi:10.2522/ptj.20060253.
- 464
- 465
- 466
- 467
- 468
- 469
- 470
- 471
- 472
- 473
- 474
- 475

476 **Table 1. Result of Systems Review**

Cardiovascular/Pulmonary	Cough, difficulty breathing, chest pain, digital clubbing, cyanosis, not present.
Musculoskeletal	Grossly Full ROM Significant hip weakness Anterior tilt, forward head. rounded shoulders posture.
Neuromuscular	Report occasional burning sensation in L5 dermatome both anterior and posterior.
Integumentary	Normal skin moisture, normal warmth.
Communication	Good understanding of written and spoken English.
Affect, Cognition, Language, Learning Style	Pt is alert and oriented to person place and time, with emotions that are typical for a 14-year-old female and prefers pictures and demonstrations as her preferred form of learning.

477

478

479

480

481

482

483

484

485

486

487 **Table 2. Results of Tests & Measures**

Tests & Measures	Initial Evaluation Results	Four Weeks	Discharge
MMT			
Transvers abdominus	2/5	2+/5	3/5
Hip Extension	3/5	3/5	4/5
Hip Abduction	3/5	3/5	4/5
Joint Play			
Lumbar P-A Central	4/6	4/6	4/6
Lumbar P-A Unilaterally	4/6	4/6	4/6
Range of Motion			
Flexion	100%	100%	100%
Extension	100%	100%	100%
Rotation R&L	100%	100%	100%
Side Bend R&L	100%	100%	100%
Observation			
In standing	Anterior pelvic tilt	Anterior pelvic tilt	Anterior pelvic tilt
Palpation			
ASIS	Symmetrical	Symmetrical	Symmetrical
PSIS	Symmetrical	Symmetrical	Symmetrical
Malleoli	Symmetrical	Symmetrical	Symmetrical

Special Testing			
Supine to sit	-	-	-
Forward flexion test	-	-	-
Numeric Pain Rating Scale			
At Best	1/10	0/10	0/10
At Worst	6/10	4/10	2/10
Oswestry Disability Index			
Percent disability	62%	20%	7%

488

489

490

491

492

493

494

495

496

497

498

499

500

501

502

503

504 **Table 3. Patient Goals**

<ol style="list-style-type: none">1. Pt will report decreased pain measure to 0/10 while at rest in order to sleep through the night in 3 weeks.2. Patient will report decreased pain measure to 0/10 in the morning in order to get ready for school in 6 weeks.
<ol style="list-style-type: none">1. Pt will decrease impaired percentage to 40-60 on the ODI in 3 weeks in order to attend to personal care.2. Pt will decrease impaired percentage to less than 40 in order to stand for 30 mins at a time and complete a task in 6 weeks.
<ol style="list-style-type: none">1. Pt will demonstrate improved muscle strength of transverse abdominus to 3/5 to fully participate in school without pain in 3 weeks.2. Pt will demonstrate improved transverse abdominus strength to 4/5 in 6 weeks in order to ambulate in the community without pain.
<ol style="list-style-type: none">1. Pt will improve gluteus strength to 4-/5 in order to avoid standing compensations in 3 weeks.2. Pt will improve gluteus strength to 4+/5 in order to perform daily chores, especially in the morning without discomfort in 6 weeks.

505

506

507

508

509 **Table 6. Intervention Progression**

Intervention	Progression								
	Tx. 1 (Eval)	Tx. 2	Tx. 3	Tx. 4	Tx. 5	Tx. 6	Tx. 7	Tx. 8	Tx. 9
Side lying hip abduction – 2sets x 10reps	†	0#	0#	0#	1#	1#	1#	2#	2#
Prone over table hip extension – 2sets x 10reps	†	0#	0#	0#	0#	0#	1#	1#	1#
Side lying clams - Theraband® Color – 2sets x 10reps	†	None	None	None	Yellow	Yellow	Yellow	Yellow	Yellow
Side Steps with Theraband® Color – 2setsx40ft	‡	Yellow	Yellow	Yellow	Yellow	Red	Red	Red	Red
Backward monster walks with Theraband® Color – 2setsx40ft	‡	Yellow	Yellow	Yellow	Red	Red	Red	Red	Red
Squats with Theraband® around knees - 2sets x 10reps	‡	Yellow	Yellow	Yellow	Yellow	Yellow	Yellow	Yellow	Yellow

Maragoul, *The Effect of a Stability and Strengthening Program on the Oswestry Disability Index in a 14-year-old Patient with Spondylolisthesis: A Case Report.*







Transverse abdominus isometrics 10seconds x 10 reps	†	<input type="checkbox"/>	<input type="checkbox"/>	‡	‡	‡	‡	‡	‡
Transverse abdominus isometrics with bent knee fall outs 2sets x 10reps	‡	‡	<input type="checkbox"/>	<input type="checkbox"/>	<input type="checkbox"/>	<input type="checkbox"/>	<input type="checkbox"/>	<input type="checkbox"/>	<input type="checkbox"/>
Transverse abdominus isometrics with mini marches 2sets x 10reps	‡	‡	<input type="checkbox"/>	<input type="checkbox"/>	<input type="checkbox"/>	<input type="checkbox"/>	<input type="checkbox"/>	<input type="checkbox"/>	<input type="checkbox"/>
Transverse abdominus isometrics with alternating shoulder flexion. 2sets x 10reps	‡	‡	‡	‡	‡	‡	<input type="checkbox"/>	<input type="checkbox"/>	<input type="checkbox"/>
Single leg stance with trampoline toss 2sets x 10reps	‡	‡	‡	Flat ground	Flat ground	Flat ground	Flat ground	Airex®	Airex®
* Tx – Treatment * Eval – Evaluation # - Pounds †– Instruction only ‡– Not performed <input type="checkbox"/> - Performed									



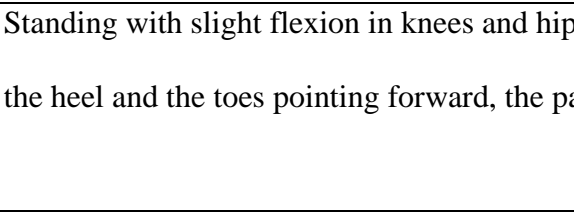
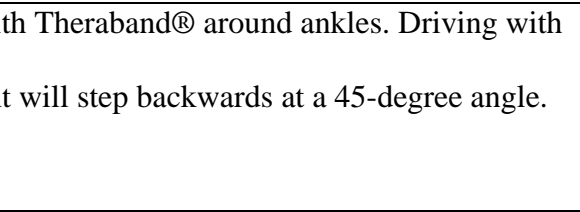
510



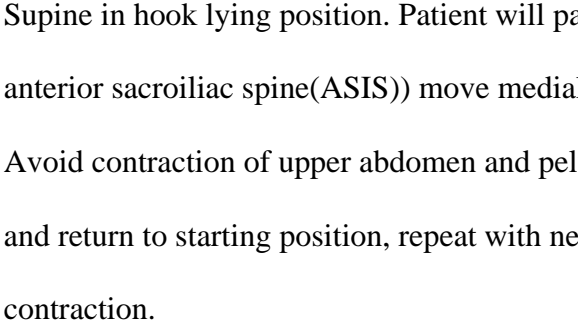
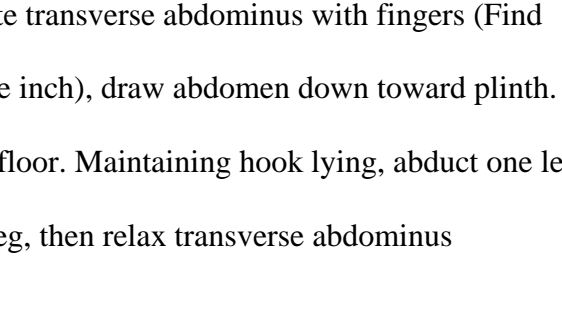
511





512


513 **Figure 1. Exercise Image Examples**

Intervention	Photo	
	Incorrect	Correct
Side lying hip abduction		
	<p>Lying on one side. Flex lower leg's knee and hip to comfort, extend upper leg's knee and hip. Lift leg up toward the ceiling making sure to avoid flexing the hip and focusing on driving with the heel.</p>	
Prone over table hip extension		
	<p>Folded over the end of a table or bed. Slight bend in weight bearing leg. Extend non-weight bearing leg maintaining full extension in knee and avoiding back extension.</p>	
Side lying clams		

	<p>Lying on one side. Both knees and hips are flexed to 90 degrees and are on top of one another.</p> <p>Without rolling torso backward, the patient will lift the top knee off the lower knee keeping the feet together.</p>	
<p>Side Steps with Theraband® Akron, OH</p>		
	<p>Standing with slight flexion in knees and hips with Theraband® around forefoot. Driving with the heel, patient will step sideways.</p>	
<p>Backward monster walks with Theraband® Akron, OH</p>		
	<p>Standing with slight flexion in knees and hips with Theraband® around ankles. Driving with the heel and the toes pointing forward, the patient will step backwards at a 45-degree angle.</p>	
<p>Squats with Theraband® Akron, OH around knees</p>		

	<p>Squat down maintaining weight through heels and pushing out into the Theraband® while avoiding forward movement of the quadriceps.</p>	
<p>Transverse abdominus isometrics</p>		
	<p>Supine in hook lying position. Patient will palpate transverse abdominus with fingers (Find ASIS (anterior sacroiliac spine)) move medial one inch), draw abdomen down toward plinth. Avoid contraction of upper abdomen and pelvic floor.</p>	
<p>Transverse abdominus isometrics with bent knee fall outs</p>		
	<p>Supine in hook lying position. Patient will palpate transverse abdominus with fingers (Find anterior sacroiliac spine(ASIS)) move medial one inch), draw abdomen down toward plinth. Avoid contraction of upper abdomen and pelvic floor. Maintaining hook lying, abduct one leg and return to starting position, repeat with next leg, then relax transverse abdominus contraction.</p>	

<p>Transverse abdominus isometrics with mini marches</p>		
	<p>Supine in hook lying position. Patient will palpate transverse abdominus with fingers (Find anterior sacroiliac spine(ASIS)) move medial one inch), draw abdomen down toward plinth. Avoid contraction of upper abdomen and pelvic floor. Maintaining hook lying, lift one foot off the plinth one inch then repeat with the other foot then finally relax transverse abdominus contraction.</p>	
<p>Transverse abdominus isometrics with alternating shoulder flexion.</p>		
	<p>Supine in hook lying position. Patient will palpate transverse abdominus with fingers (Find anterior sacroiliac spine(ASIS)) move medial one inch), draw abdomen down toward plinth. Avoid contraction of upper abdomen and pelvic floor. Maintaining hook lying, flex one shoulder overhead then the next one then finally relax contraction.</p>	

<p>Single leg stance with trampoline toss</p>	 <p>Standing on one leg, drawing in transverse abdominus, and maintaining slight knee and hip flexion. Patient will throw a two-pound medicine ball at a trampoline and catch it with both hands while maintaining single leg stance.</p>
--	---

514