

Instrument Assisted Soft Tissue Mobilization and Conservative Management of Shoulder Pain in an Elderly Male: A Case Report



Dana McCoy, BS

Department of Physical Therapy, University of New England, Portland, Maine

Background

- Shoulder pain is a frequent complaint among the elderly population, numerous etiologies cause shoulder joint pain such as osteoarthritis, adhesive capsulitis, and rotator cuff disease (impingement, tendonitis, and cuff tear).¹
- A conservative treatment for shoulder pathology is Augmented Soft Tissue Mobilization (ASTM) that uses specifically designed solid instruments to perform manual therapy.
- Sound Assisted Soft Tissue Mobilization (SASTM®) is a technique which uses ceramic polymer tools with resonating capability. Limited evidence exists to support the use of SASTM® as a manual therapy treatment.

Purpose

The purpose of this case report is to illustrate the physical therapy management of shoulder pain in an elderly male by describing intervention techniques, such as SASTM®, joint mobilization, and therapeutic exercise, using the patient/client management model.

Case Description

HS was a very active 83 year old male with right shoulder pain and decreased range of motion. He reported a 6 month history of chronic intermittent shoulder pain without a known injury. He completed all of his activities of daily living independently, however when reaching and lifting objects, he favored his left arm due to right shoulder pain. He lived with his wife in a two story home and enjoyed gardening and cooking. Past/ Current Medical History: high blood pressure, diabetes, and stage III desmoplastic melanoma on his left upper extremity. Previous surgical history of Achilles tendon repair, Tommy John right elbow surgery, and removal of Melanoma skin cancer on the left upper arm.

Examination

Systems Review	Results
Musculoskeletal	Impaired gross strength and range of motion in all motions of the R shoulder secondary to pain.
Neuromuscular	Previous history of chronic intermittent R hand paresthesias which reduced with wrist brace worn at night.
Cardiovascular	Vitals not assessed
Integumentary	Not Impaired

Tests and Measures	R Shoulder	Initial Exam	Visit 13
Active Range of Motion	See Graph		
Manual Muscle Test	Limited secondary to decrease ROM	Flexion, Abduction, External Rotation: 2-/5 Internal Rotation: 4+5	Flexion, Abduction, External Rotation: 2/5 Internal Rotation: 5/5
Special Test	Empty Can Lift Off Speed's Hawkin's Kennedy Cross Body Adduction Active Radial & Median Nerve	Positive Positive Negative Negative Negative Negative	Positive Negative Negative Negative Negative Negative
Pain		Rest: 3/10; Activity:8/10 Mild tenderness: R supraspinatus muscle, spine of scapula, greater tuberosity of humerus, proximal bicep, distal tricep	Rest: 2/10 Activity: 6/10. Mild tenderness along R supraspinatus muscle, greater tuberosity of humerus
Outcome Measure	Disabilities of Arm, Hand, Shoulder (DASH)	36/100	26/100

Normal DTR's, full and pain free cervical ROM, nearly neutral posture with R shoulder slightly elevated in comparison with the L.

PT Diagnosis & ICD-9

Practice Pattern 4D; Impaired Joint Mobility Motor Function, Muscle Performance, and Range of Motion Associated With Connective Tissue Dysfunction.
ICD-9 719.41 Pain in Joint Involving Shoulder Region.²

Interventions



Figure 1: Sound Assisted Soft Tissue Mobilization (SASTM®) tools available at the clinic. Top Row left to right, Tools #6, and 4. Bottom row, left to right, Tools #3, 2, and 1.

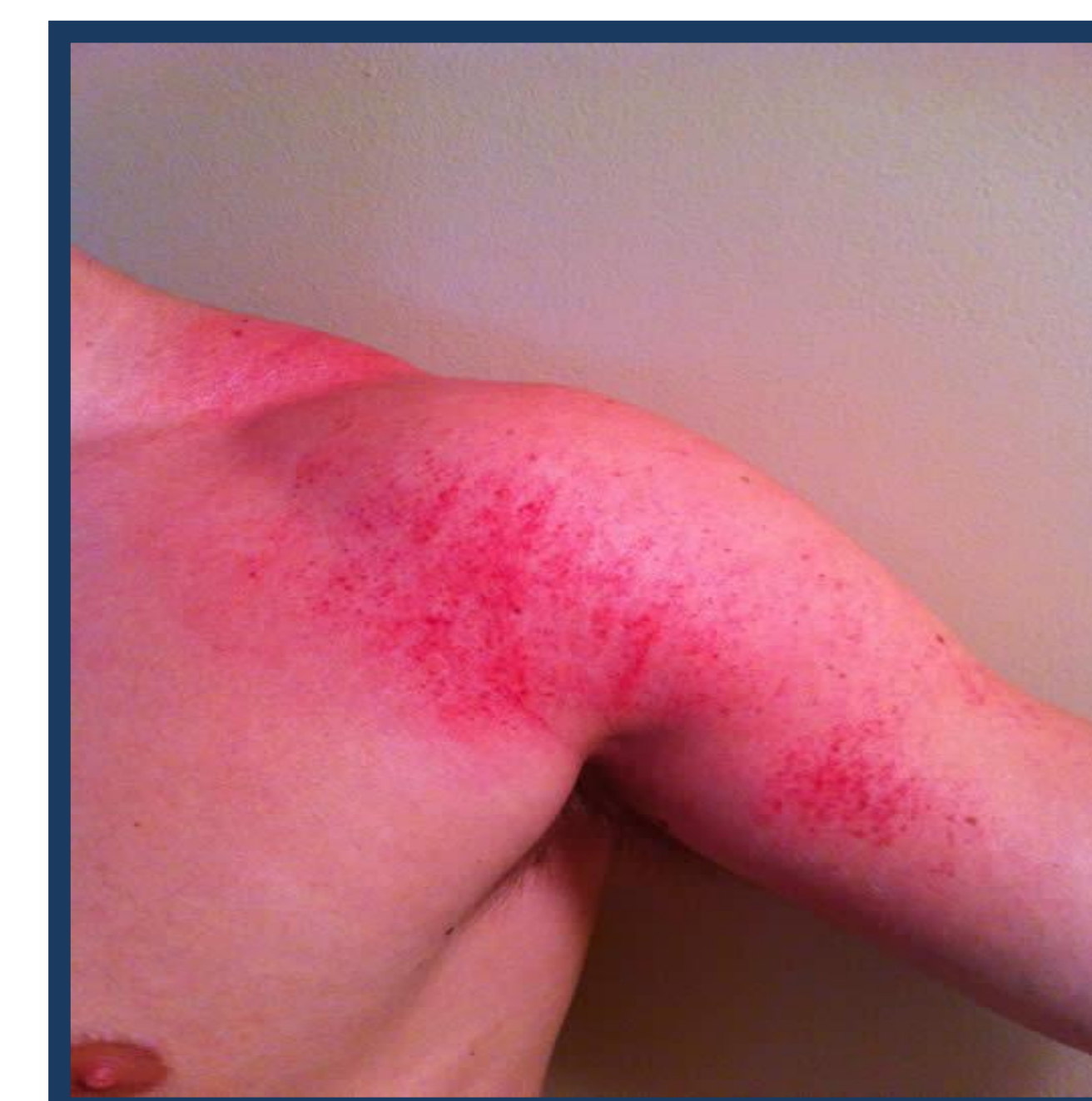

Figure 2: Petechiae following a Sound Assisted Soft Tissue Mobilization Treatment (SASTM®) treatment

Manual Therapy

- SASTM®: Intermediate-Deep Layers R shoulder, 1x wk
- Joint Mobilization: R Glenohumeral & Scapulothoracic, Grade 2-3, 2x wk
- Nerve Gliders/Tensioners: Median Nerve, one time in week 6
- Strain-counterstrain: Supraspinatus TP, one time in week 6

Therapeutic Exercise

- AAROM: All R shoulder motions, 2x wk
- Resisted Rotator Cuff Strengthening: All motions, 1-2#, 2x wk
- HEP: R shoulder stretching all directions; bilateral scapular retraction with level 1 resistance, added in week 5

Outcomes

- Therapy sessions completed: 13 over 7 weeks- with primary author
- Reduction in pain
- Improved R shoulder ROM
- Increased R shoulder strength
- Minimal petechiae along bicep and anterior shoulder following SASTM® treatments
- Improvement in DASH score

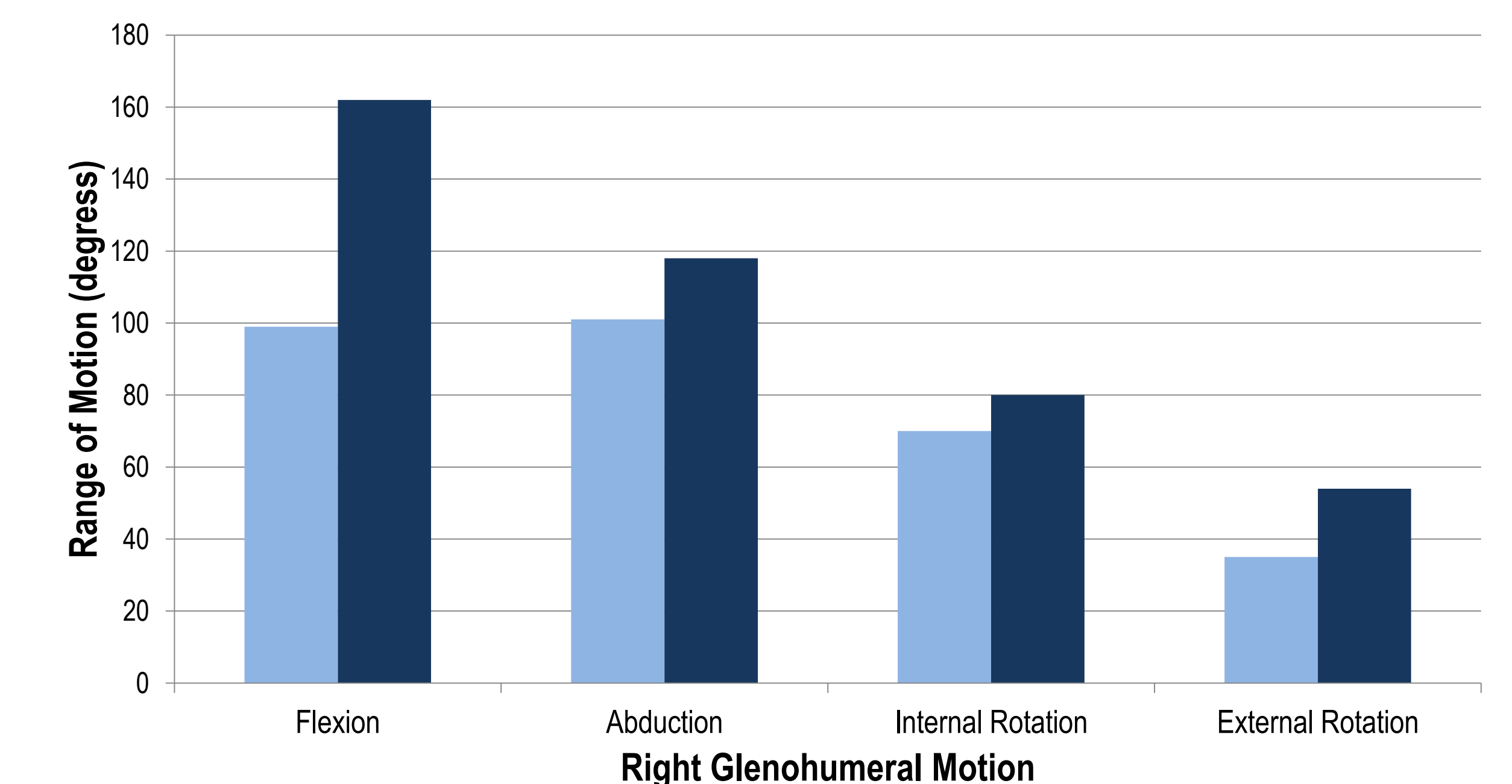


Figure 3: Range of motion values for the R Glenohumeral joint; flexion, abduction, internal rotation, and external rotation measured on initial examination and visit 13.

Discussion

Physical Therapists working with the elderly population with nonspecific shoulder pain may incorporate instrument assisted soft tissue mobilization into their procedural interventions. Despite the lack of evidence for this intervention on human models, it appears that SASTM® helped improve impairments in this patient case. Further studies involving the use of instruments on human models with rotator cuff tendonitis, supraspinatus impingement, and osteoarthritis is required to understand the benefits of this intervention.

References

1. Lin, J.C, et al. Nonsurgical Treatment for Rotator Cuff Injury in the Elderly. *Journal of American Medical Directors Association*. 2008; 9: 626-632.
2. American Physical Therapy Association. *Guide to physical therapist practice* (2nd ed.). Alexandria, VA: (2003).